

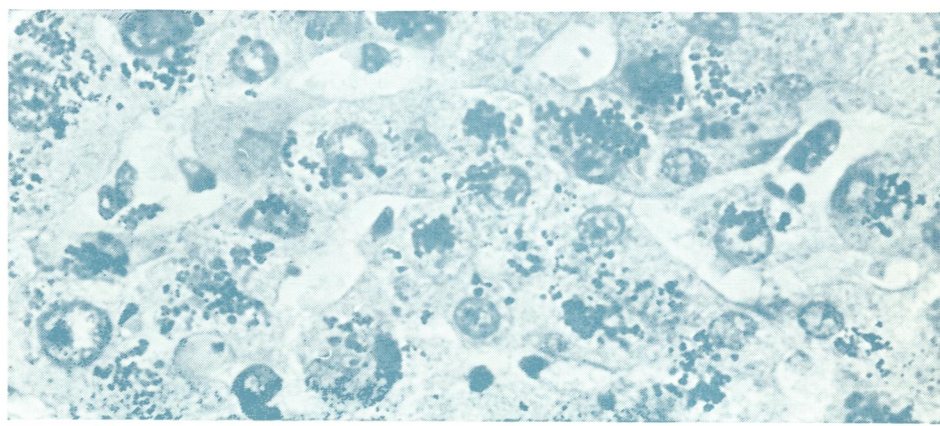
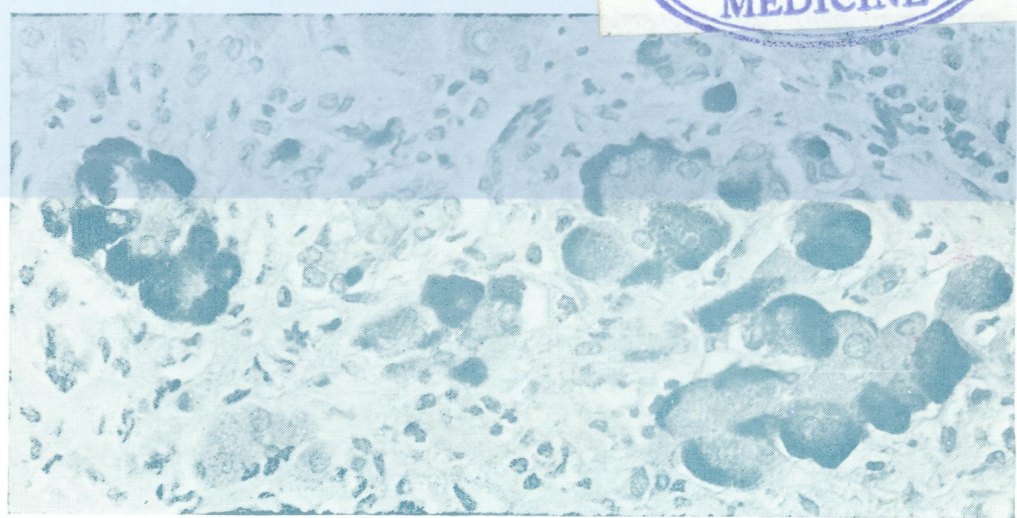

Jo 5896

DR

Journal of Clinical Pathology

The Journal of the Association of Clinical Pathologists

Vol. 31, No. 5, May 1978



'Ground-glass' hepatocytes stained with Shikata's orcein technique ... 400. See Fig. 8b, p. 401.

Wilson's disease: increased amounts of copper (dark granules) demonstrated by rhodamine ... 640. See Fig. 12a, p. 406.

J Clin Pathol: first published as on 1 May 1978. Downloaded from <http://jcp.bmj.com/> on 23 April 2018 by guest. Protected by copyright.