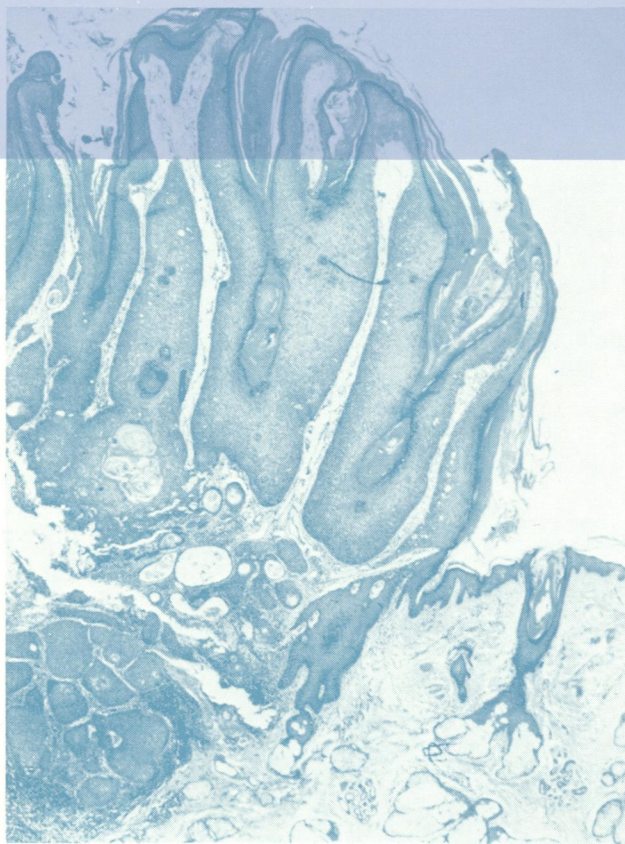


# Journal of Clinical Pathology

*The Journal of the Association of Clinical Pathologists*

Vol. 28, No. 6, June 1975



Low-power view of mainly protuberant lesion. Note that part of lesion extends downwards into the dermis. See fig 1, page 466

