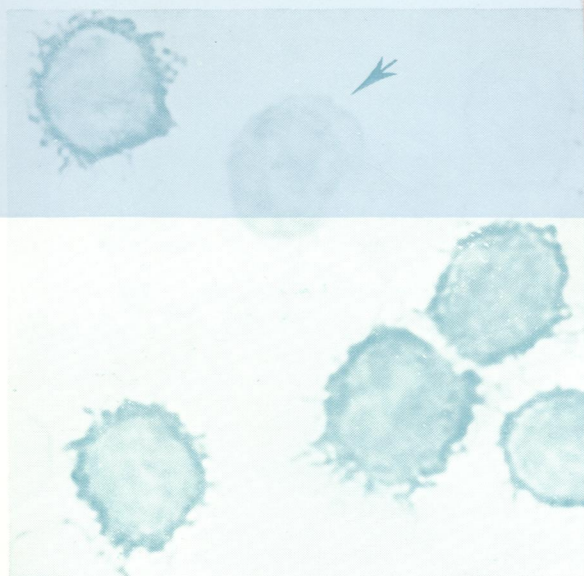



Journal of Clinical Pathology

The Journal of the Association of Clinical Pathologists

Vol 33, No 7, July 1980



(Above) Bone marrow sample from a case of prolymphocytic leukaemia stained for IgM. A negative small lymphocyte is arrowed. $\times 2600$. See Fig. 2 (a), page 612. (Right) Peripheral blood sample from a case of centrocytic lymphoma stained for IgM. A strongly positive cell (single arrow) showing villous membrane staining is seen together with a second more weakly stained cell (double arrow) with a smooth membrane profile. Note the 'wire ring' effect imparted by membrane staining in this cell and the clearly visualised cleft nuclear outline. $\times 2000$. See Fig. 3, page 613.

