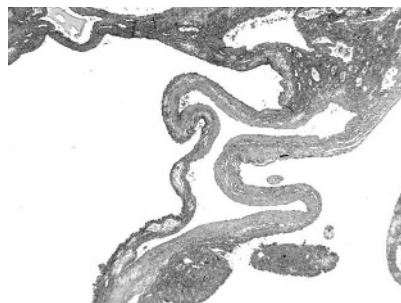



**Figure 2** Case 2. Multicystic tumour with thickened septa.

rare, and is often misdiagnosed as renal carcinoma with a cystic component.<sup>1-5</sup> Here, we report two consecutive cases of multilocular cystic renal oncocytoma.

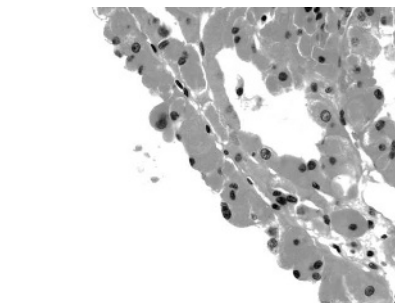
A 67 year old man presented with a sudden pain in his left back. He had no relevant medical history. Physical examination showed a microscopic haematuria.

Ultrasonography, computed tomography (CT) scan, and magnetic resonance imaging (MRI) uncovered a large heterogeneous tumour in the left kidney. The tumour measured 7 cm in its greatest diameter, and was largely cystic with multilocular septa. Enhancement of the septa and the nodular central component showed up well on MRI (fig 1). A radical nephrectomy was performed. After a follow up of 26 months, the patient is well without recurrence or metastasis.

A 47 year old woman without relevant antecedents presented with diffuse abdominal pain. A CT scan and MRI studies were performed and showed a small 3.5 cm multilocular cystic tumour in the upper pole of the left kidney. Multiple thickened septa were more easily seen on the MRI than the CT scan. Septa and wall were well enhanced on contrast imaging. A partial nephrectomy was performed, and eight months later the patient is well.

On gross examination, both tumours were predominantly cystic, multilocular, with thickened septa, and with no central scar. Microscopically, septa were covered by cuboidal or columnar eosinophilic cells (figs 2, 3). The cytoplasm was abundant and granular. The nuclei were round with one or several nucleoli. No severe atypia or necrosis was noted. No hobnail cells were found. Mitotic activity was low (less than one mitotic figure/10 high power fields). A small area of classic solid tubulocystic oncocytoma was identified in each case. In the first case, tumour cysts focally invaded the perinephric fat. No vascular invasion was seen. On immunohistochemistry, tumour cells were diffusely positive for epithelial membrane antigen and pancytokeratin and focally positive for cytokeratin 7. Staining for cytokeratin 20, high molecular weight cytokeratin, and CD10 was negative.

Oncocytoma is a renal adenoma that makes up 5–7% of all renal tumours.<sup>1,2</sup> Classically, oncocytoma is a solid mass that develops in the renal parenchyma with a central fibrous scar. Oncocytoma with prominent macroscopic cystic features is very unusual and should be distinguished from other renal cystic tumours, such as multilocular clear cell carcinoma or cystic nephroma.<sup>3-5</sup> Preoperatively, in our cases, no distinction was possible by imaging studies;



**Figure 3** Case 2. Typical oncocytic cells with eosinophilic cytoplasm covering the tumour septa.

in particular, no central scar was seen. Therefore, these tumours were classified as suspected cystic tumours, Bosniak's class 3.

Only microscopic examination can identify the characteristic oncocytic cells covering the tumour septa. However, a minor component of usual oncocytoma is also often seen.

In the first case, focal invasion of the perinephric adipose tissue was present. This unusual feature is seen in less than 10% of oncocytomas in large series, and has no effect on the prognosis.<sup>1,2</sup> Oncocytomas may present limited central microcystic degeneration but a prominent multicystic presentation is very unusual. Only isolated cases have been reported in the English literature.<sup>3-6</sup> The diagnosis cannot be made radiologically. In the literature, one case resembled a haemorrhagic cyst on imaging.<sup>6</sup> In a recent series of 28 cases of atypical renal cystic tumours evaluated by imaging guided biopsy, one case of cystic oncocytoma was diagnosed.<sup>7</sup>

The prognosis of this variant is excellent; metastasis has not been reported. The clinical course appears to be very similar to that of usual oncocytoma and these tumours may be managed by partial nephrectomy.<sup>8</sup>

**X Leroy, S Aubert, L Lemaitre, J Haffner, J Biserte, B Gosselin**

Departments of Pathology, Urology, and Radiology, University Hospitals, 59037, Lille, France; x-leroy@chru-lille.fr

## References

- 1 **Perez-Ordóñez B**, Hamed G, Campbell S, *et al*. Renal oncocytoma: a clinicopathologic study of 70 cases. *Am J Surg Pathol* 1997;**21**:871–83.
- 2 **Amin MB**, Crotty TB, Tickoo SK, *et al*. Renal oncocytoma: a reappraisal of morphologic features with clinicopathologic findings in 80 cases. *Am J Surg Pathol* 1997;**21**:1–12.
- 3 **Ogden BW**, Beckman EN, Rodriguez FH. Multicystic renal oncocytoma. *Arch Pathol Lab Med* 1987;**111**:485–6.
- 4 **Schmidt PR**, Bock D, Gasser G, *et al*. Multicystic renal oncocytoma. *Urologe A* 1991;**30**:253–5.
- 5 **Sakido N**, Kawai K, Takashima H, *et al*. Renal oncocytoma mimicking hemorrhagic renal cyst. *Int J Urol* 1995;**2**:336–8.
- 6 **Komada K**, Nagano K, Akimoto M, *et al*. Small renal oncocytoma with central cystic degeneration. *Int J Urol* 2004;**11**:110–13.
- 7 **Harisinghani MG**, Maher MM, Gervais DA, *et al*. Incidence of malignancy in complex cystic renal masses (Bosniak category III). *AJR Am J Roentgenol* 2003;**180**:755–8.
- 8 **Marszalek M**, Ponzholzer A, Brossner C, *et al*. Elective open nephron-sparing surgery for renal masses: single-center experience with 129 consecutive patients. *Urology* 2004;**64**:38–42.

## CALENDAR OF EVENTS

Full details of events to be included should be sent to Mike Muir, Editorial Assistant; email: jclinpath@bmjgroup.com

### Diagnostic Histopathology of Breast Disease

8–12 May 2006, Hammersmith Hospital and Imperial College, London, UK  
Further details: Wolfson Conference Centre, Hammersmith Hospital, Du Cane Road, London W12 0NN, UK. (Tel +44 (0)20 8383 3117/3227/3245; Fax +44 (0)20 8383 2428; e-mail wcc@ic.ac.uk)

### Practical Pulmonary Pathology

25–28 July 2006, Brompton Hospital, London, UK  
Further details: Professor B Corrin, Brompton Hospital, London SW3 6NP, UK. (Tel +44 (0)20 7351 8425; Fax +44 (0)20 7351 8293; e-mail b.corrin@ic.ac.uk)

### Diseases and Tumours of the Salivary Glands

21–22 October 2006, Landeskliniken Salzburg, Paracelsus Medical University, Austria  
Further details: Dr J Beck-Mannagetta, Maxillofacial Surgery/SALK-PMU, Müllner Hauptstr. 48, A-5020 Salzburg, Austria. (Tel +43 662 4482 3601; Fax +43 662 4482 884; e-mail j.beck-mannagetta@salk.at)

## BOOK REVIEW

### The Oxford Dictionary of Medical Quotations

Authored by P McDonald. Oxford: Published by Oxford University Press, 2004, £9.99 (soft-back), pp 212. ISBN 019856598

"A book of quotations ... can never be complete." Or can it? The *Oxford Dictionary of Medical Quotations* is a diverse yet comprehensive compilation of over 2500 medically related proverbs and quotations. Whether you are a medical history buff, avid quotation hound, or just trying to find that perfect quote to enhance your next presentation, this book is sure to be indispensable. The quotes are listed under both author and keywords to help you find a specific quote or subject with ease. However, if all you seek are a few moments with the profound to comical musings of doctors, poets, or politicians you will find this book surprisingly difficult to put down.

**R M Hamilton**

## CORRECTION

Adley MA, Assaf HA, Hussein M. Expression of CD1d in human scalp skin and hair follicles: hair cycle related alterations. *J Clin Pathol* 2005;**58**:1278–82. The surname of the first author was spelt incorrectly. The correct name is Adly MA.