

W1  
50 5896

READING ROOM

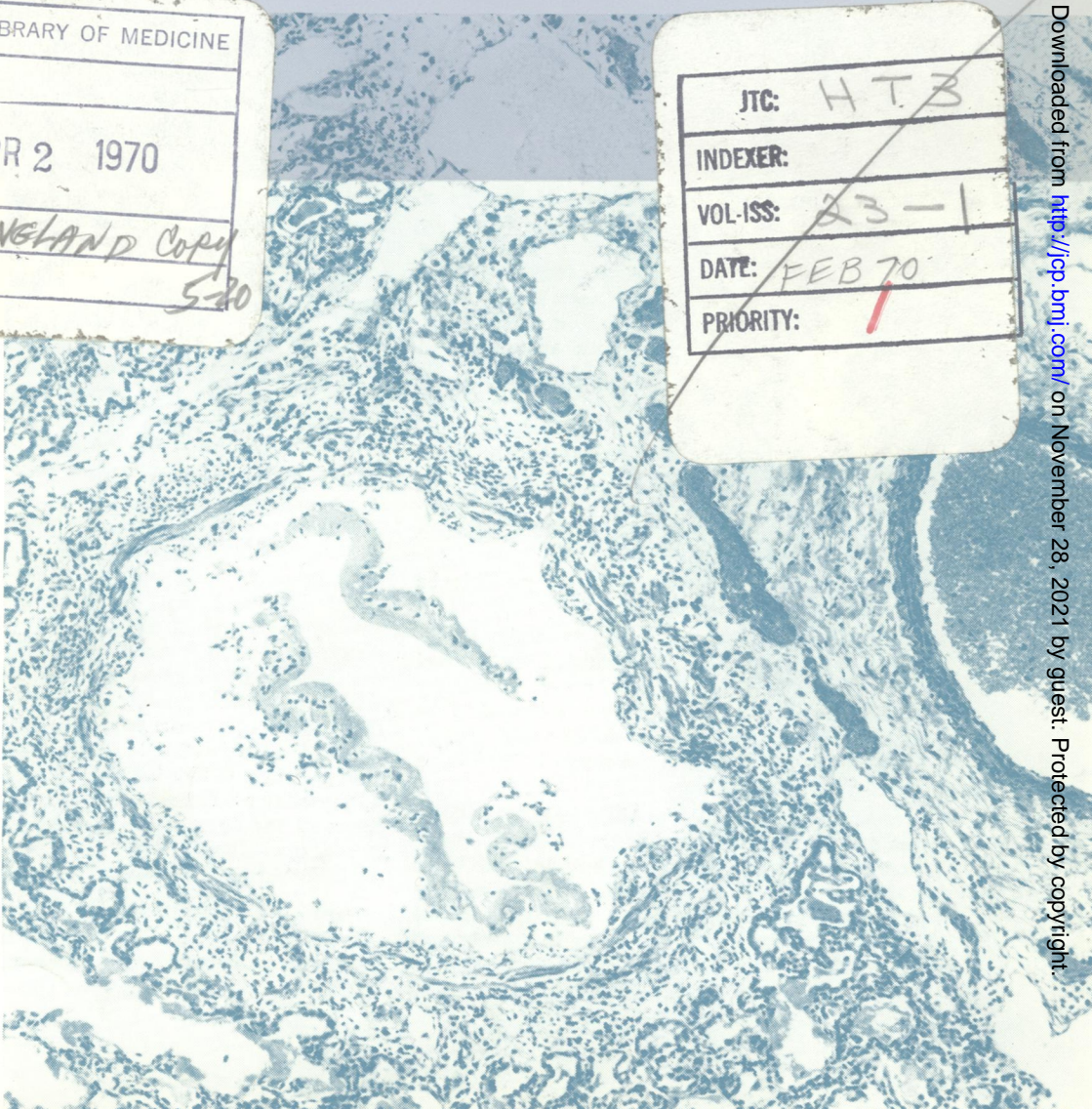
# Journal of Clinical Pathology

The Journal of the Association of Clinical Pathologists

Vol. 23, No. 1, February 1970

NATIONAL LIBRARY OF MEDICINE	
RECD. APR 2 1970	
INDEX	ENGLAND Copy
INPUT	5-20

JTC:	HT3
INDEXER:	
VOL-ISS:	23-1
DATE:	FEB 70
PRIORITY:	1



*Interstitial pneumonia. The mucosa of the bronchiole has been totally destroyed; a slough of cell debris and fibrin occupies the lumen. Alveolar walls contain a mononuclear cell infiltration and are lined by hyaline membranes.*

*Connective tissue is oedematous and lymphocytes are prominent.*

*—see Fig. 11, page 15*