

READING ROOM

Journal of Clinical Pathology

The Journal of the Association of Clinical Pathologists

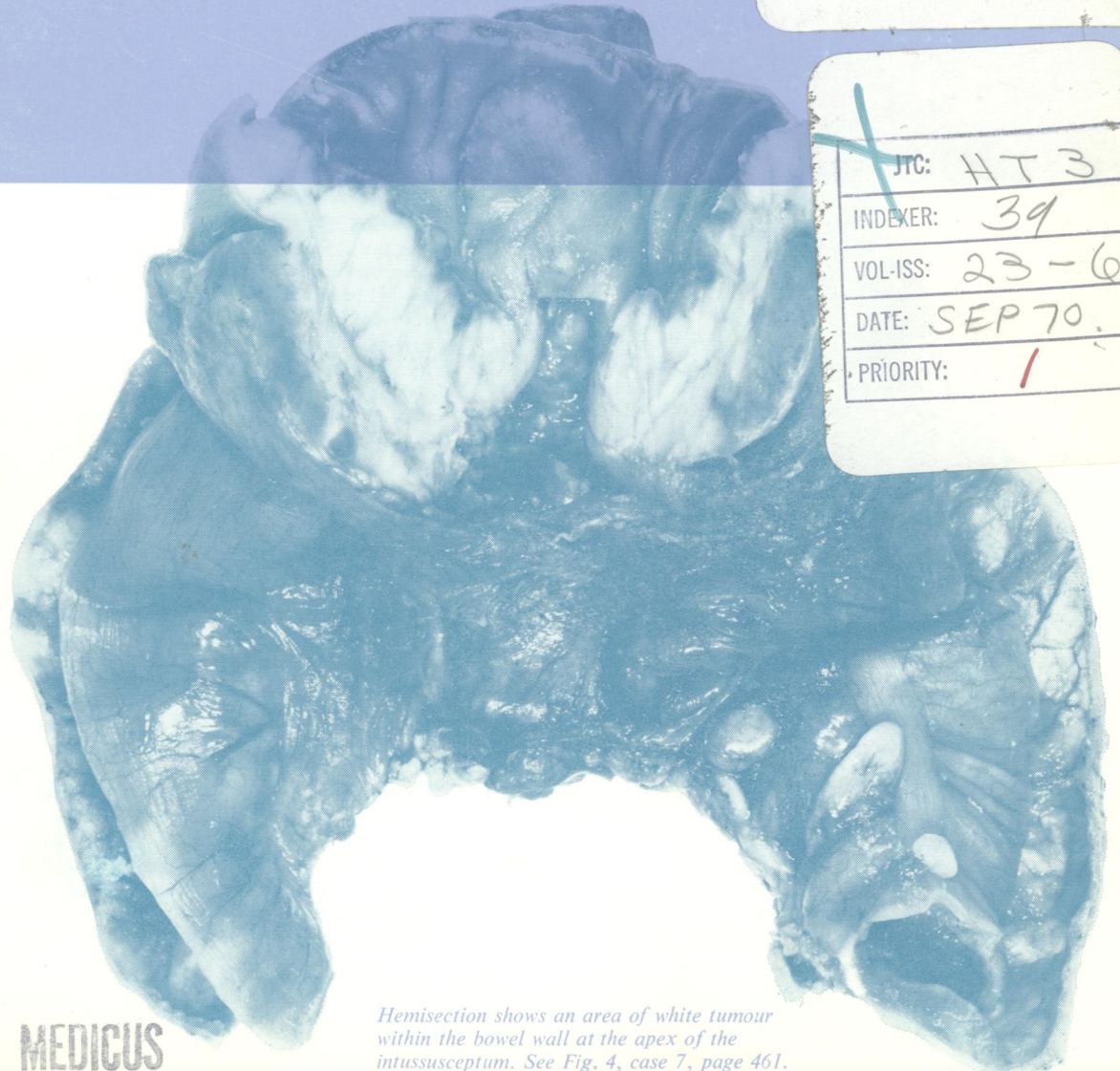
Vol. 23, No. 6, September 1970

NATIONAL LIBRARY OF MEDICINE

RECD. DEC 1 1970

INDEX DEC 1 0 1970

INPUT DEC 23 1970



JTC: HT 3
 INDEXER: 39
 VOL-ISS: 23-6
 DATE: SEP 70
 PRIORITY: 1

Hemisection shows an area of white tumour within the bowel wall at the apex of the intussusceptum. See Fig. 4, case 7, page 461.

INDEX MEDICUS