

Ref. 23/6P  
R

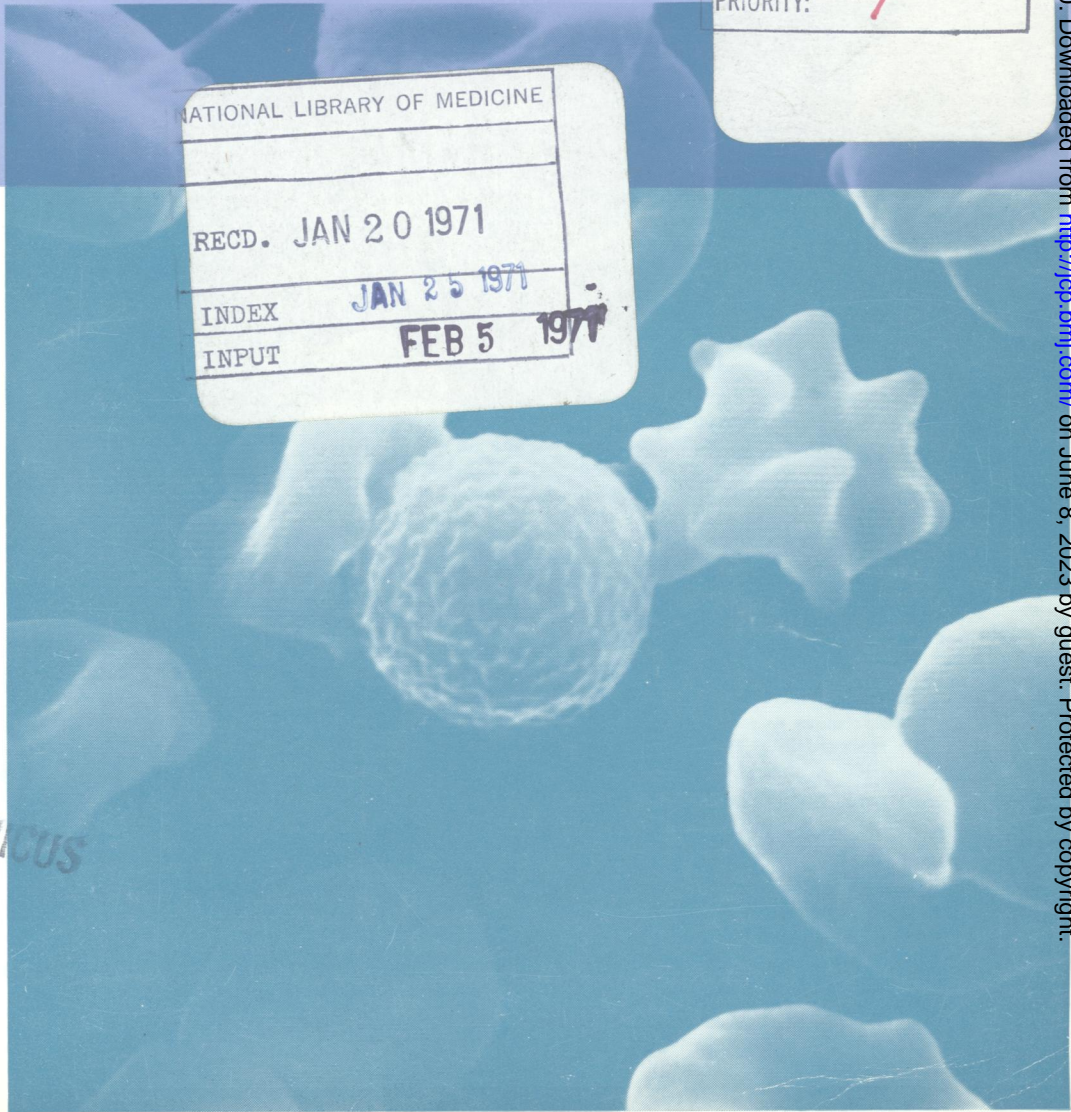
WI  
505896 M  
READING ROOM

# Journal of Clinical Pathology

*The Journal of the Association of Clinical Pathologists*

Vol. 23, No. 8, November 1970

JTC:	HT3
INDEXER:	39
VOL-ISS:	23-8
DATE:	NOV 70
PRIORITY:	1



INDEX MEDICUS

J Clin Pathol: first published as on 1 November 1970. Downloaded from <http://jcp.bmj.com/> on June 8, 2023 by guest. Protected by copyright.

Scanning electron microscopy from case 2, showing typical 'wool-ball' appearance of spherocytes. See Fig. 3, page 713.