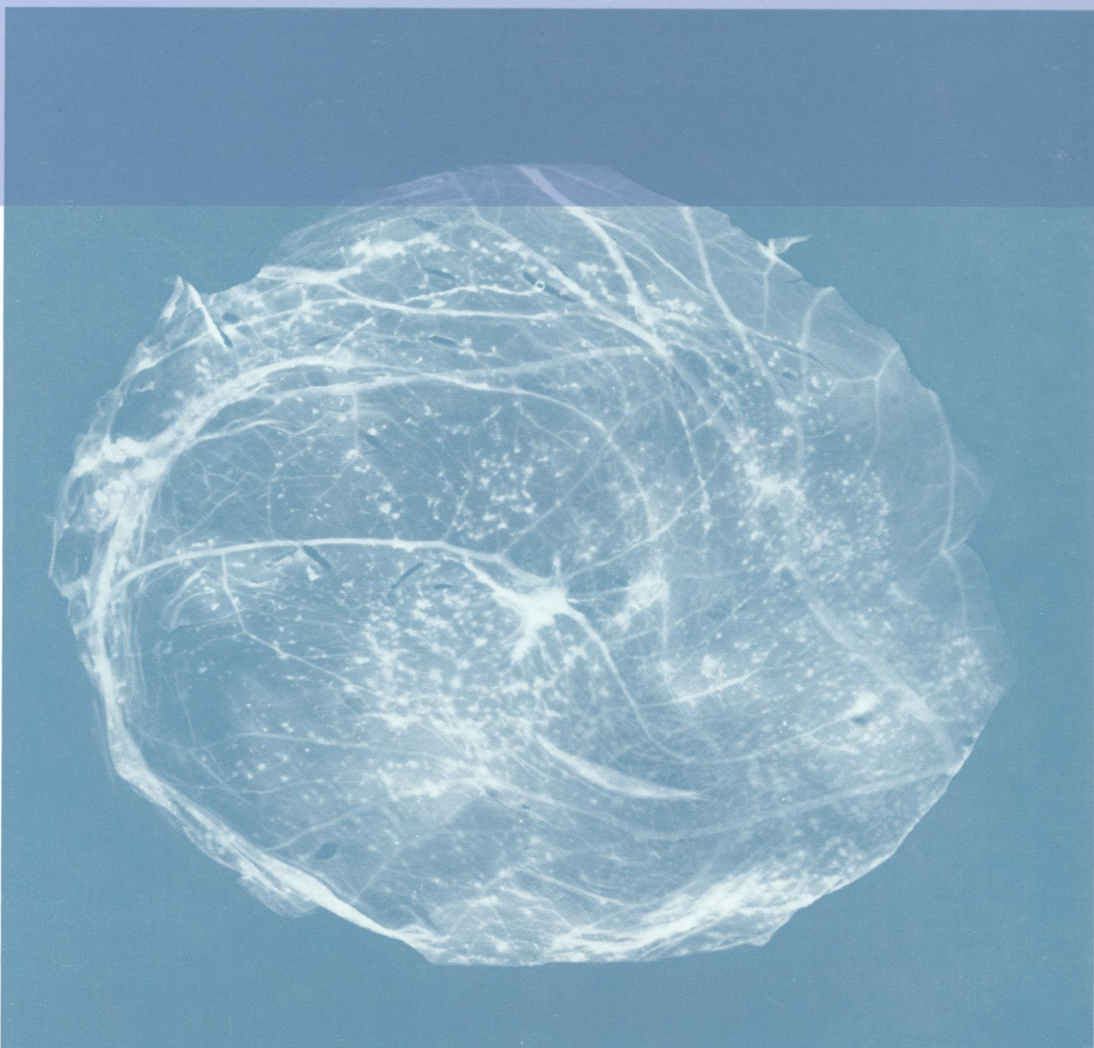



5896
READING ROOM

Journal of Clinical Pathology

The Journal of the Association of Clinical Pathologists

Vol. 24, No. 7, October 1971



Candida albicans:
infection of the
chorioallantoic
membrane after 48
hours (twelfth day of
embryo develop-
ment). See Fig. 1,
page 646