

50 5896
READING ROOM

Journal of Clinical Pathology

The Journal of the Association of Clinical Pathologists

Vol. 25, No. 8, August 1972

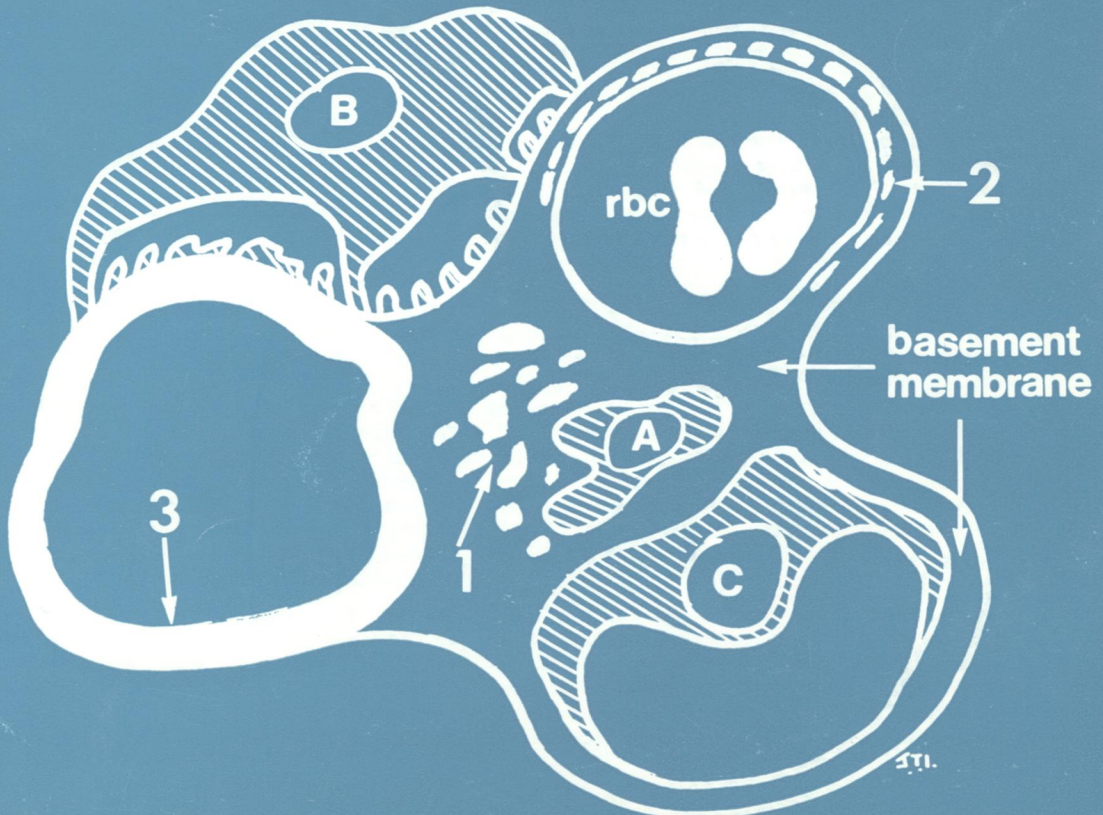



Diagram of glomerular capillary lobule showing patterns of distribution of fibrin:
1 Granular fibrin scattered within mesangium.
2 Beaded in discontinuous linear distribution either subendothelial or within basement membrane.
3 Diffuse uniform throughout capillary wall.
A. Mesangial cell;
B. Epithelial cell attached by foot processes;
C. Endothelial cell within capillary lumen.
See Fig. 2, page 659.