

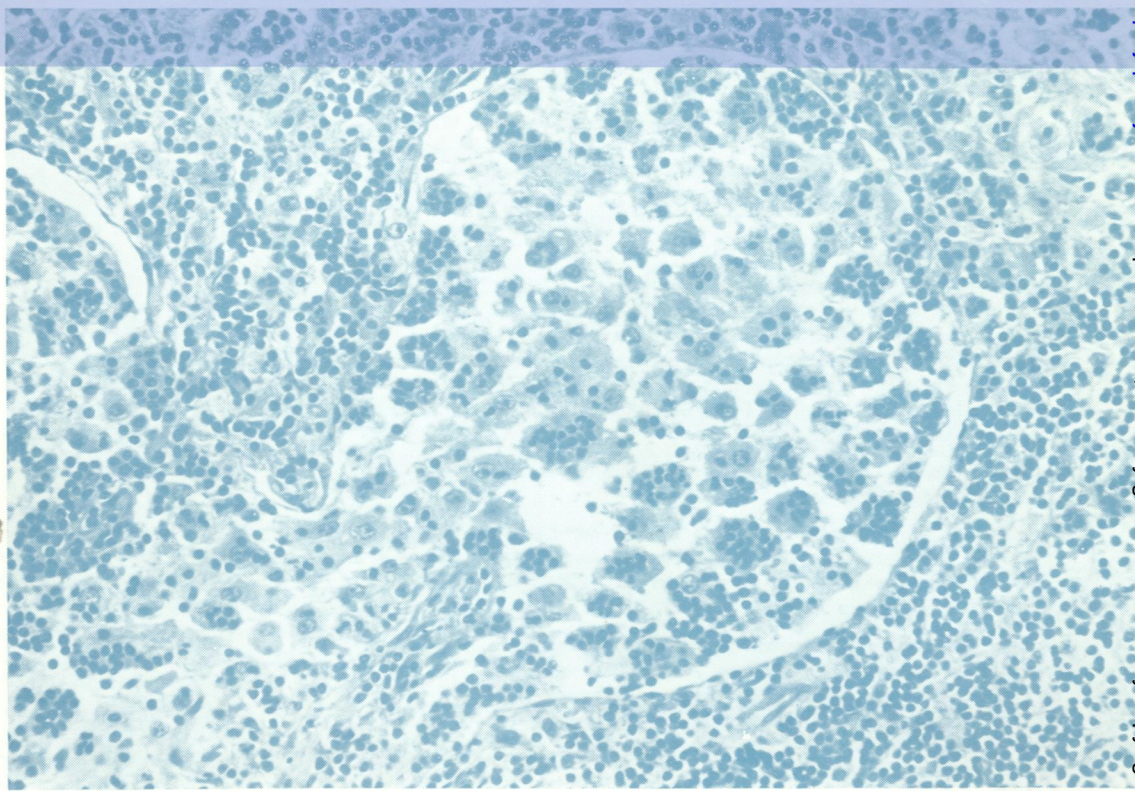

05896
READING
ROOM

Ref.

Journal of Clinical Pathology

The Journal of the Association of Clinical Pathologists

Vol. 26, No. 7, July 1973



distended lymph
node sinus in which
many histiocytes
contain
phagocytosed
lymphocytes
(emperipolesis).
See fig. 4 page 465

J Clin Pathol: first published as on 1 July 1973. Downloaded from <http://jcp.bmj.com/> on September 27, 2021 by guest. Protected by copyright.