


WI

J05896

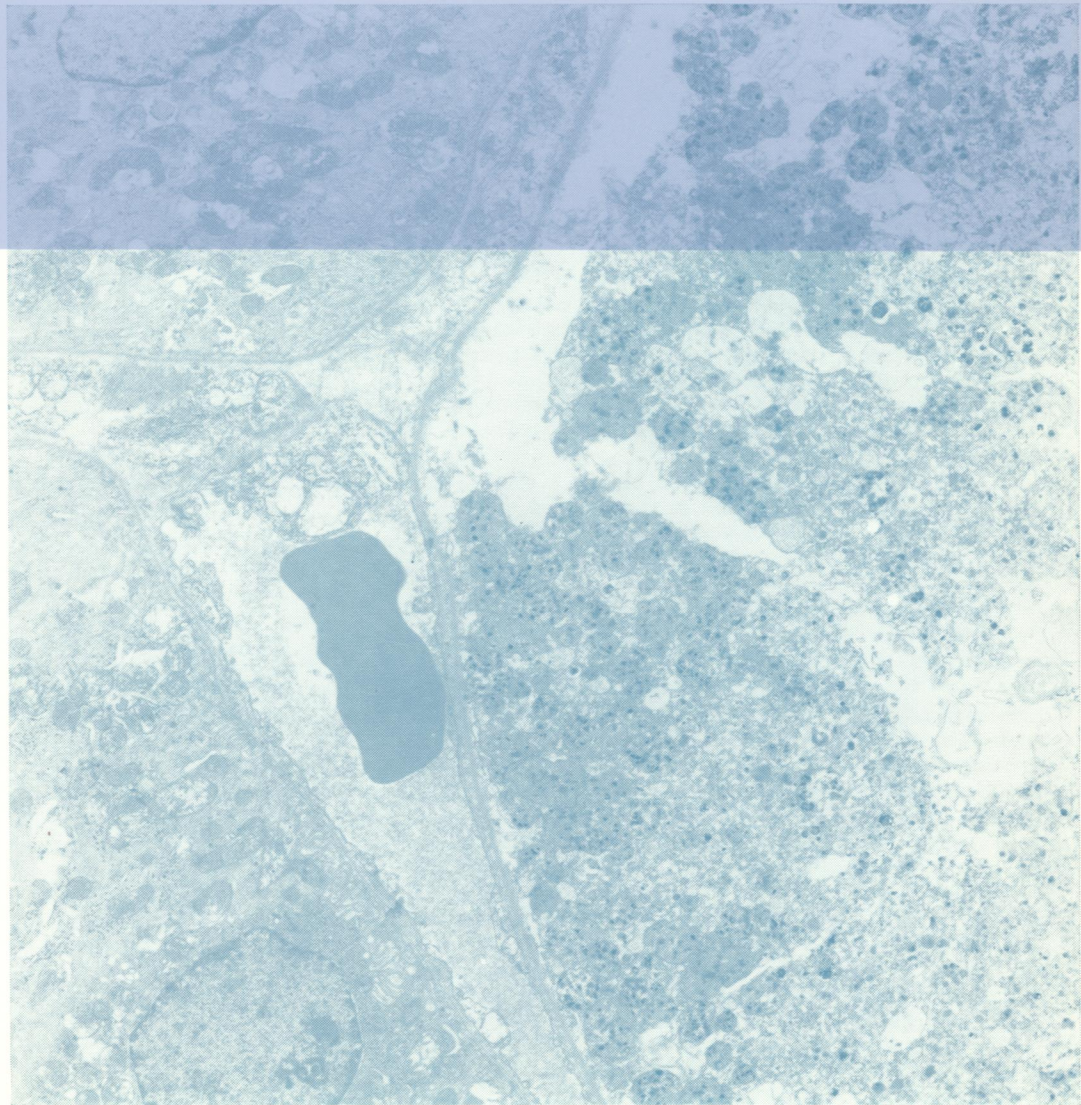
Copy 2

# Journal of Clinical Pathology

*The Journal of the Association of Clinical Pathologists*



Vol. 27, No. 1, January 1974



erotic proximal  
ule in an anuric  
following  
ministration of  
reuric chloride.  
tochondria in  
ying stages of  
solution can be  
n. A peritubular  
illary is immedi-  
ly adjacent to  
necrotic cells  
d two unaffected  
ules can be seen.  
fig. 6a, page 8

J Clin Pathol: first published as on 1 January 1974. Downloaded from <http://cp.bmj.com/> on June 24, 2022 by guest. Protected by copyright.