

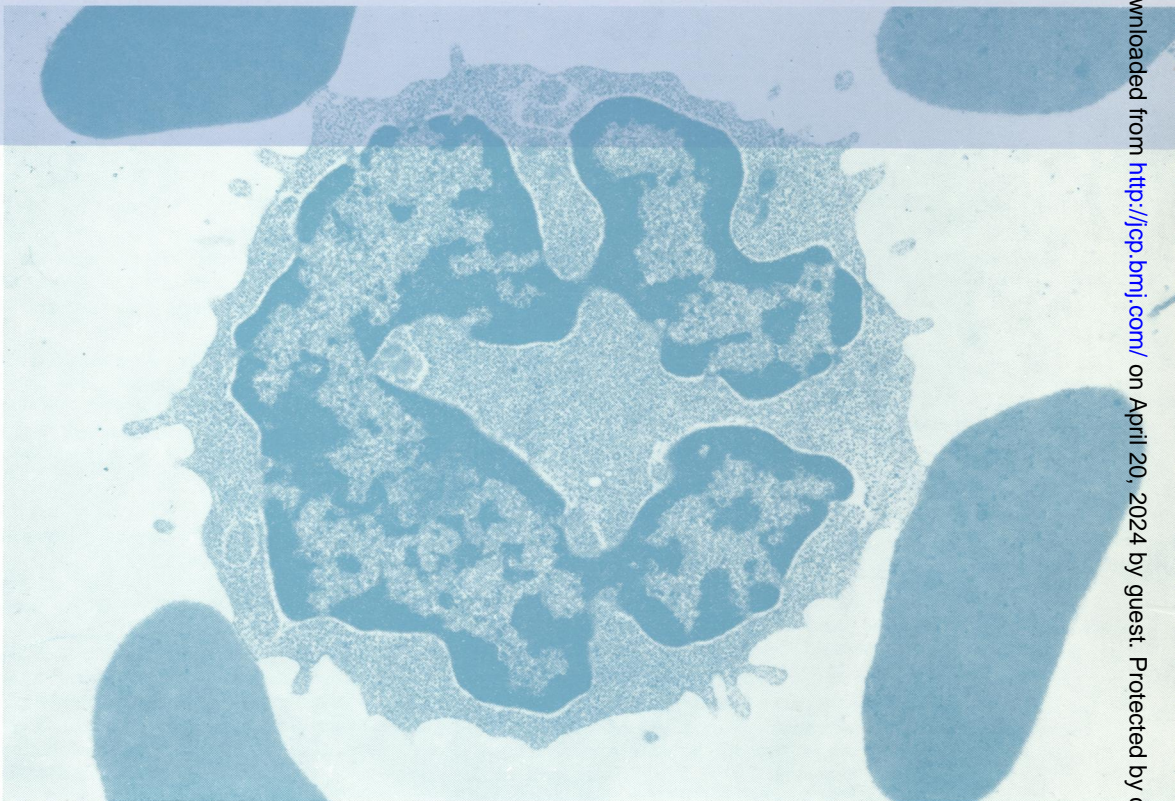

W 10 5896

COPY 2

Journal of Clinical Pathology

The Journal of the Association of Clinical Pathologists

Vol. 27, No. 11, November 1974



Electron micrograph of a typical haemic cell, at the centre of a platelet, showing the attachment areas of the sheep cells. (fig 2, page 854.)