

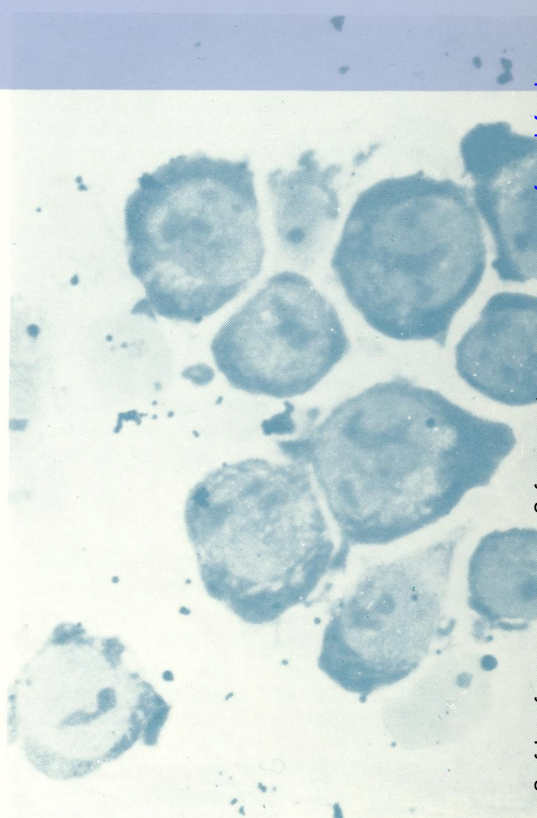
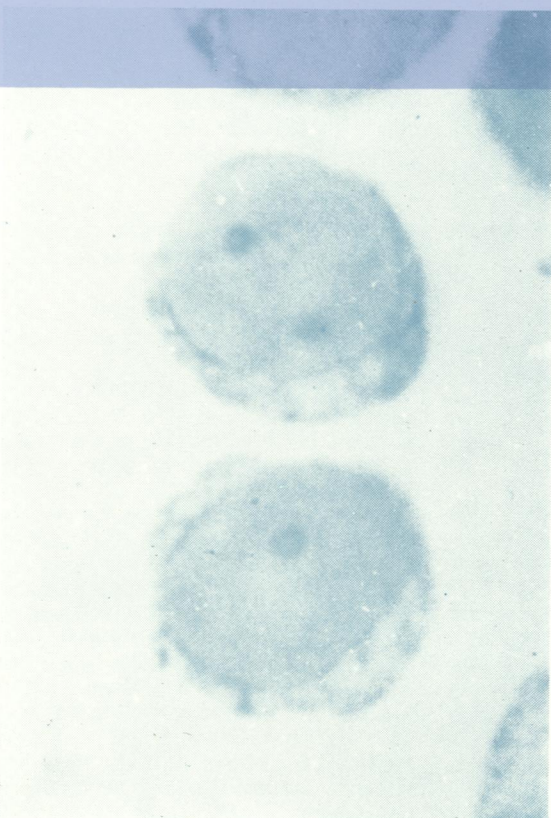

W1
Jo 5896

COPY 2

Journal of Clinical Pathology

The Journal of the Association of Clinical Pathologists

Vol. 27, No. 4, April 1974



Small lymphocytes stained with Azure C (left), and lymphocytes after 72 hours' culture with phytohaemagglutinin stained with Azure C (right). See figs 1 and 2, page 338.