

5896

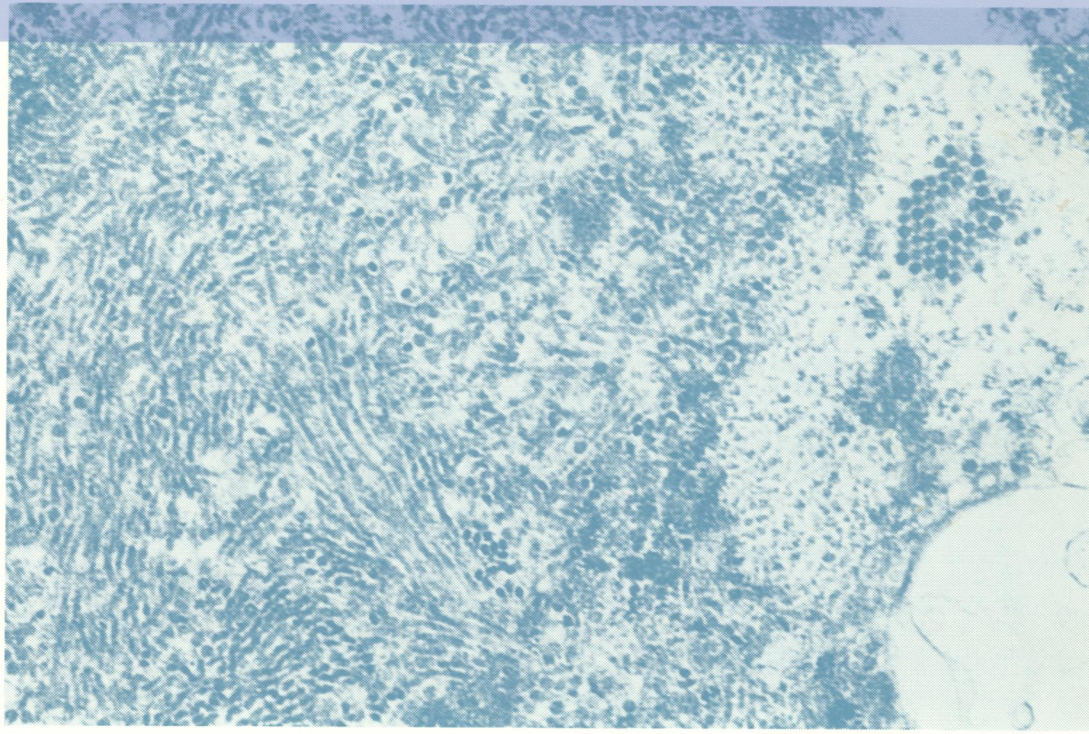

READING ROOM

REF.

Journal of Clinical Pathology

The Journal of the Association of Clinical Pathologists

Vol. 27, No. 5, May 1974



Thin section of progressive multi-focal leucoencephalopathy-affected brain. Intranuclear filamentous and spherical polyomavirus particles and intracytoplasmic pseudo-crystalline array of spherical virus particles (nucleus is at the left of the micrograph). See fig 1, page 342.

J Clin Pathol: first published as on 1 May 1974. Downloaded from <http://jcp.bmj.com/> on June 25, 2024 by guest. Protected by copyright.