

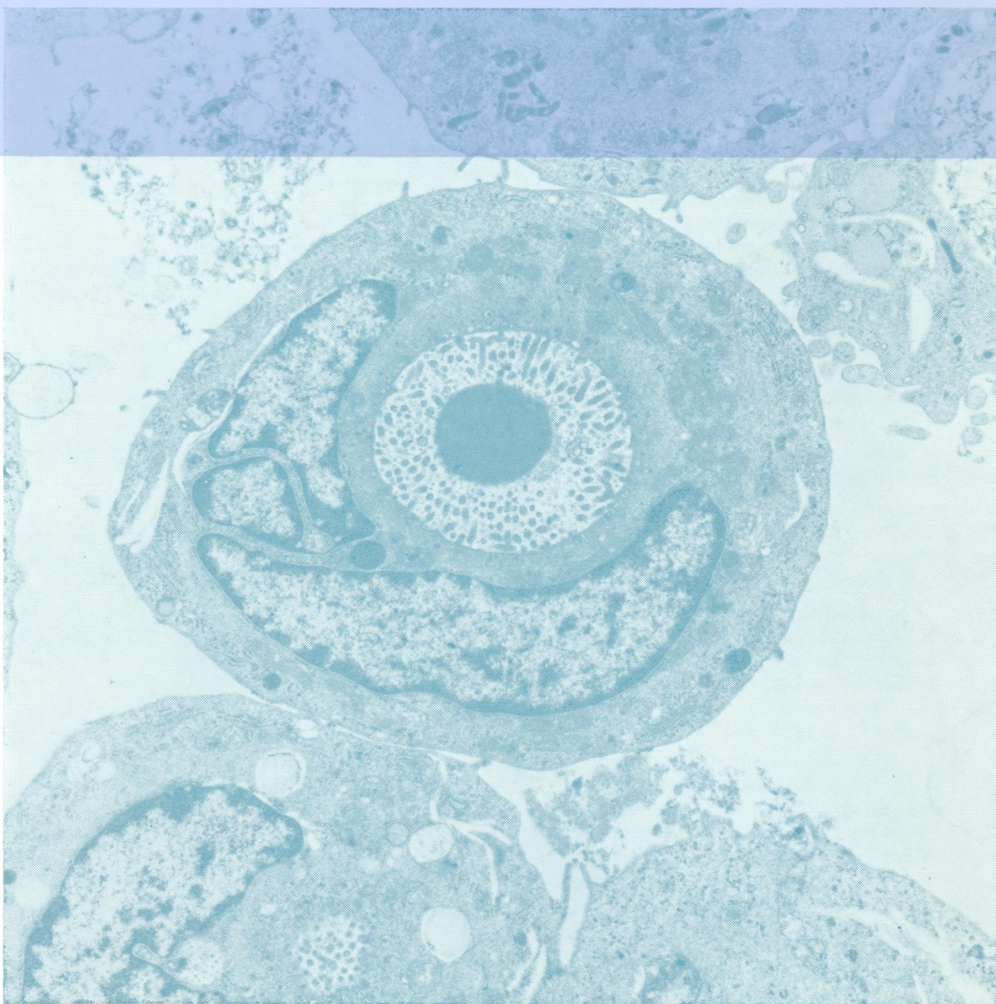

W1
Jo 5896

copy 2

Journal of Clinical Pathology

The Journal of the Association of Clinical Pathologists

Vol. 28, No. 12, December 1975



A free tumour cell with a central microvillus-lined cavity. At the centre of this is a uniformly electron-dense body. The cavity is surrounded by secretion granules (barely visible), and outside these are many mitochondria. See fig 6, page 933.