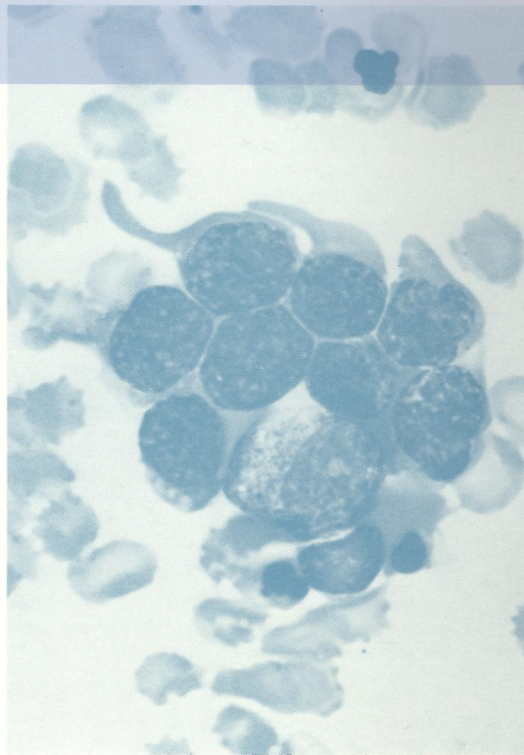
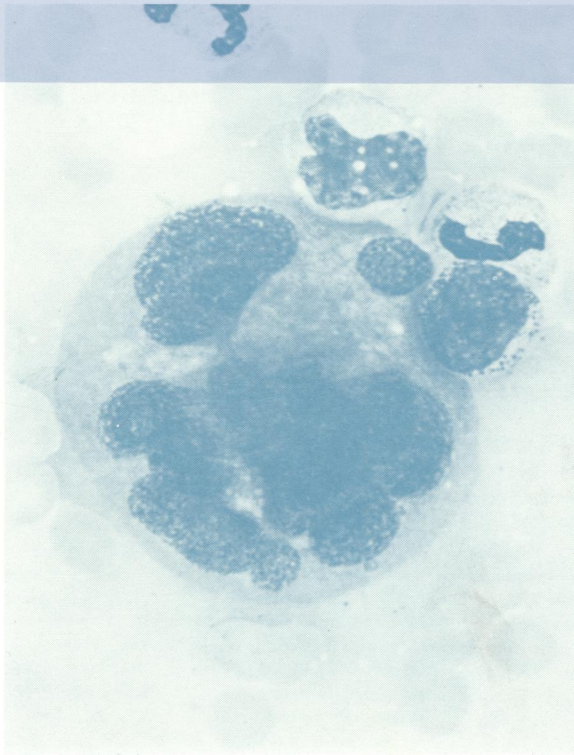



70 5896 READING ROOM

# Journal of Clinical Pathology

*The Journal of the Association of Clinical Pathologists*

Vol. 28, No. 4, April 1975



*Blood and bone marrow appearances in two patients with unusual megaloblastic anaemia with multinucleate erythroblasts, septicaemia, and acute renal failure. See figs 2g and 4g, pages 327 and 330.*