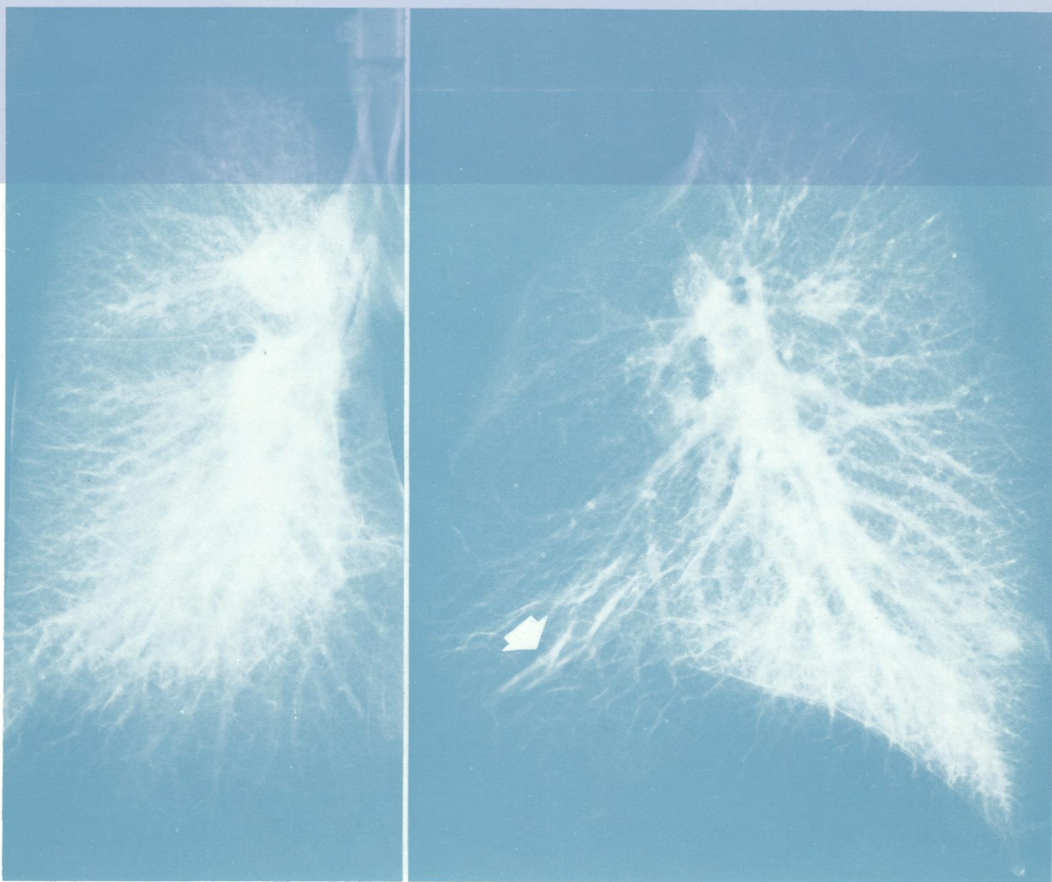



J05896

Journal of Clinical Pathology

The Journal of the Association of Clinical Pathologists

Vol. 28, No. 5, May 1975



Frontal view of a formaldehyde vapour inflated right lung showing moderate basal oedema seen as a ground glass whiteness. Multiple oedema line shadows are also present.

Lateral view showing moderate posterior basal intra-alveolar oedema which decreases from the base towards the upper lobe. Note the thick bands of interstitial oedema shown anteriorly (arrow) but without intra-alveolar component. See fig 9 a, b, pages 357-366.