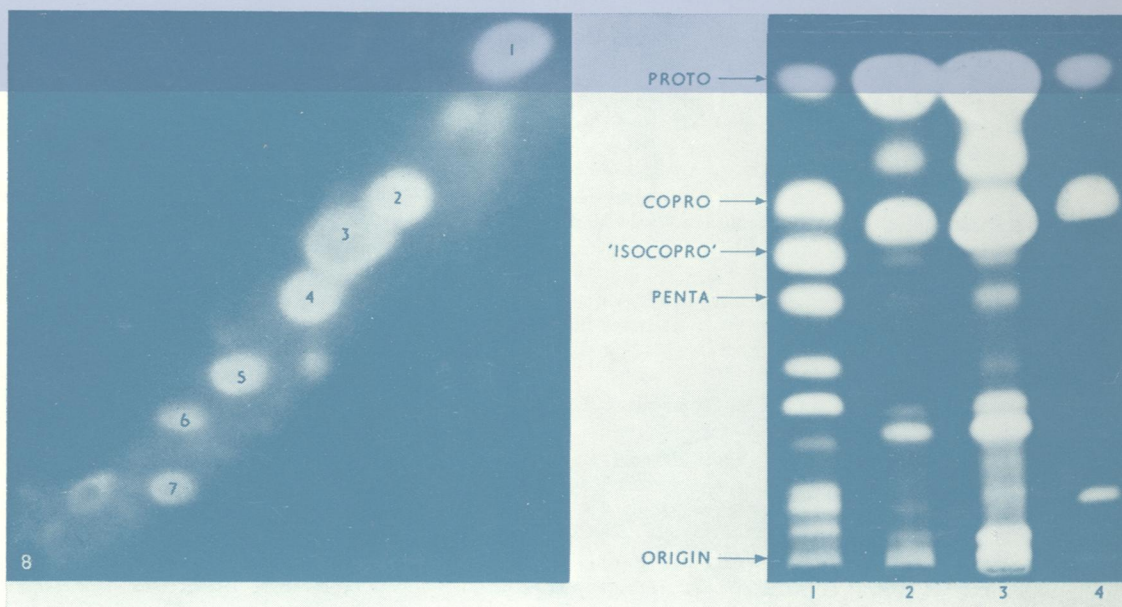



Journal of Clinical Pathology

The Journal of the Association of Clinical Pathologists

Vol. 28, No. 8, August 1975



Left: Two-dimensional thin-layer chromatography of porphyrin esters from the faeces of a patient with PCTS photographed under ultraviolet light:

1 = protoporphyrin; 2 = coproporphyrin; 3 = isocoproporphyrin; 4, 5, 6 = penta-, hexa-, and heptacarboxylate porphyrins; 7 = hydroxyisocoproporphyrin; 8 = origin.

Right: Screening test for 'isocoproporphyrin'. Thin-layer chromatography of porphyrin esters from faeces of patients with PCTS (1) and VP (2, 3) and a normal subject (4) photographed under ultraviolet light. See figs 1 and 2, pages 603 and 604