

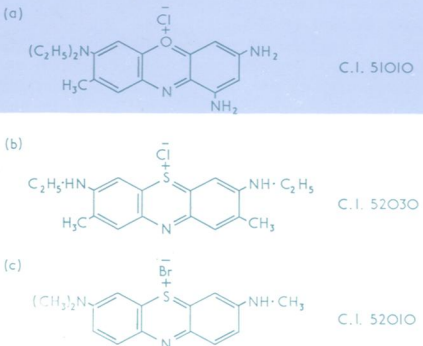
50 5896

copy 2

Journal of Clinical Pathology

The Journal of the Association of Clinical Pathologists

Vol. 29, No. 12, December 1976



(Left) Structures and Colour Index numbers of dyes used to stain reticulocytes: (a) brilliant cresyl blue; (b) new methylene blue; (c) azure B. See fig 1, page 1060.
 (Right) Photomicrograph of reticulocyte film obtained with purified azure B. Note the absence of any dye deposit. $\times 1000$. See fig. 4 page 1062.

