

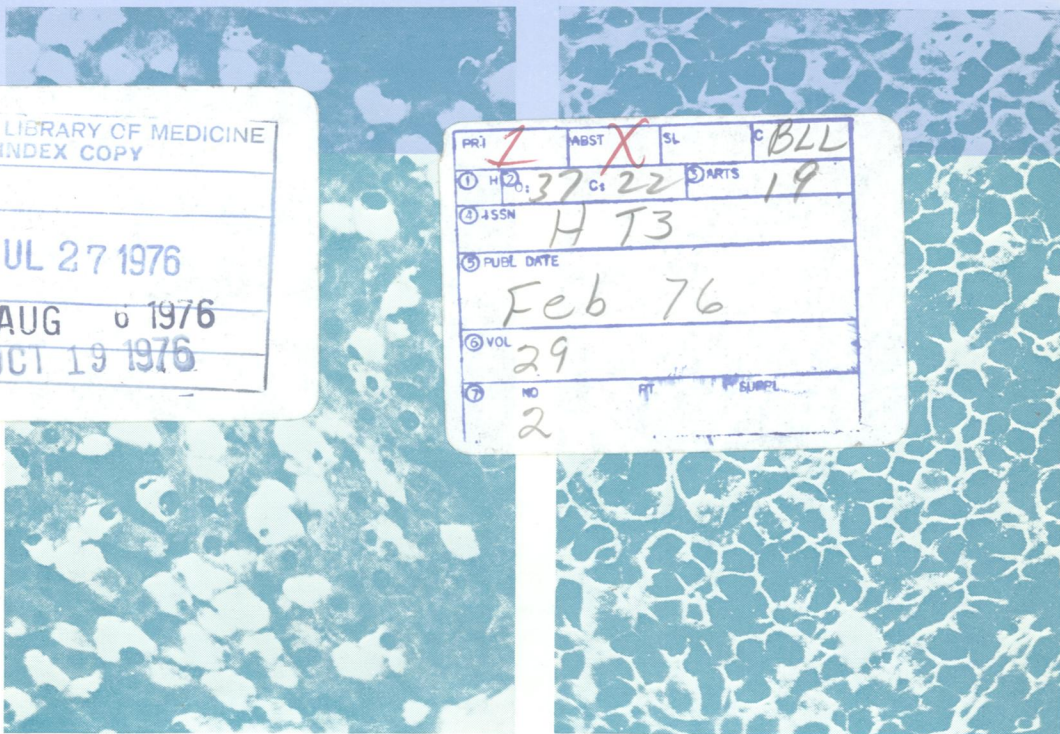
05896

DR

Journal of Clinical Pathology

The Journal of the Association of Clinical Pathologists

Vol. 29, No. 2, February 1976



(Left) Chronic persistent hepatitis: diffuse homogenous bright fluorescence in the cytoplasm of the hepatocytes distributed diffusely in the liver ($\times 193$). (Right) Chronic aggressive hepatitis: HBs Ag-specific fluorescence mostly demonstrated in the membrane of the liver cells. In a few hepatocytes the cell membrane along with the cell periphery is also positive; only a few cells show bright cytoplasmic fluorescence ($\times 176$) (See figs 1 and 2, pages 95 and 96).

NATIONAL LIBRARY OF MEDICINE
INDEX COPY

RECD. JUL 27 1976

INDEX AUG 6 1976

INPUT OCT 19 1976

PRJ	1	ABST	X	SL	C	BLL
① H	37	② C	22	③ ARTS	19	
④ ISSN	H 73					
⑤ PUBL DATE	Feb 76					
⑥ VOL	29					
⑦ NO	2		PT	SUPPL		