

# Technical methods

## Cone-biopsy histology report

R. A. MCINROY, H. R. GRIMSHAW, P. HARRISON *Department of Pathology, St. Luke's Hospital, Bradford*

Sanerkin and Fraser (1975) describe a technique designed to facilitate orientation of blocks and sections (and diminish the workload of technician and pathologist) and they refer to the problems inherent in the handling and sectioning of cervical cone-biopsies. They effect orientation by means of a stained track made in the anterior lip of the cervix with a needle but the technique in its simplicity falls short of the comprehensiveness and precision which are technically possible and desirable.

In this hospital a routine for handling cervical cone-biopsies and their subsequent histological examination and reporting has, after trial of several methods over a period of years, evolved and become established. This routine and the merits claimed for it are outlined.

The cone-biopsy specimen, *unfixed* and unopened (preferably), with a suture inserted at 12 o'clock is submitted to the laboratory in a plastic bag to prevent drying of the epithelial surface. The specimen is then cut and opened out enabling, after fixation, a series of orientated blocks to be cut (fig 1).

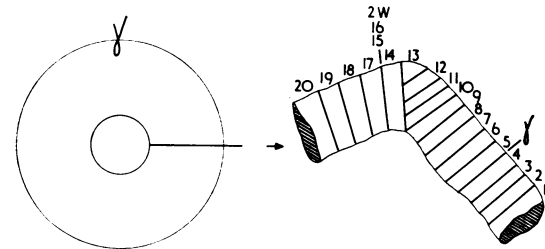


Fig 1 Shows diagrammatically the ring of cone-biopsy tissue (with suture at 12 o'clock) and the series of orientated blocks cut, from right to left, after the cone has been opened out and fixed. A change in the angle of sectioning, sometimes necessitated by the curvature of the specimen, is indicated after block 13, and wedge blocks (2W, blocks 15 and 16) may sometimes require to be cut from the cervical stroma to restore to 90° the angle between the plane of sectioning and the epithelial surface.

The cut edges made by the pathologist on opening the cone are clearly marked.

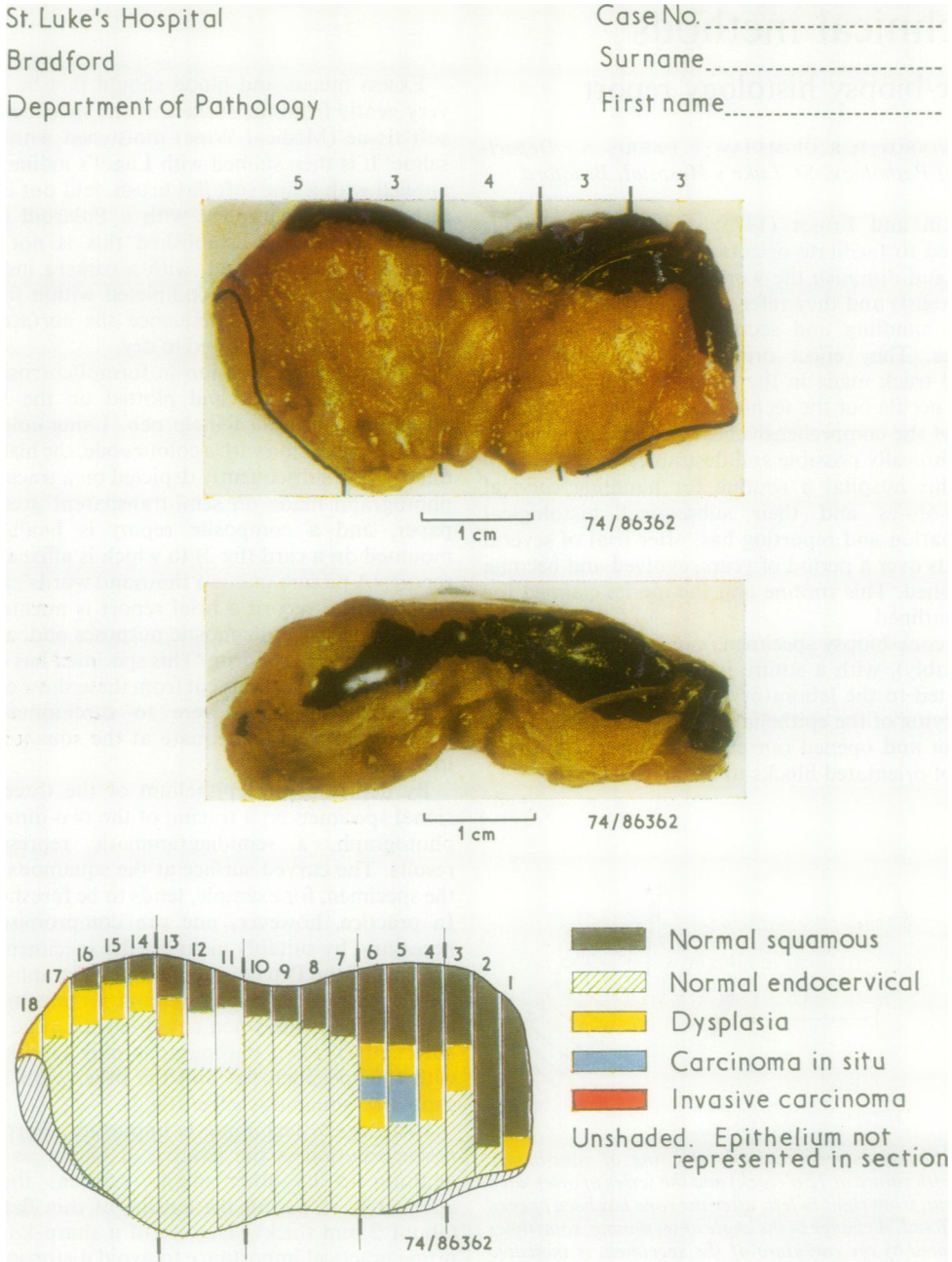
Excess mucus and blood should first be removed very gently from the surface of the specimen using a soft tissue (Medical Wipe) moistened with isotonic saline. It is then stained with Lugol's iodine solution applied with a fine soft flat brush, laid out in a Petri dish, and photographed with a Polaroid camera<sup>1</sup>. Once a routine is established this is not a time-consuming exercise and, with a camera installed in the laboratory, can be completed within five to 10 minutes. During this sequence the surface of the cervix must not be allowed to dry.

After overnight fixation in formol/corrosive solution, blocks are cut and plotted on the Polaroid photograph using a felt-tip pen. Using colour pencils, in conjunction with a colour code, the histological findings are subsequently depicted on a tracing of the photograph made on semi-transparent greaseproof paper, and a composite report is finally issued mounted on a card (fig 2) to which is affixed a typed report. 'A picture paints a thousand words', and with this pictorial record a brief report is normally adequate for routine diagnostic purposes and, as in this example, takes the form, 'This specimen has been cut into 18 blocks. Sections cut from these show epithelial dysplasia (moderate-severe to carcinoma-in-situ). Excision appears inadequate at the squamous edge in blocks 17 and 18.'

By depicting the epithelium of the three-dimensional specimen on a tracing of the two-dimensional photograph, a semidiagrammatic representation results. The curved surface at the squamous edge of the specimen, for example, tends to be foreshortened. In practice, however, one can compromise, when necessary, by suitably inclining the specimen against the wall of the Petri dish before photography to provide a representative picture, and some compromise may also be made when colour-shading the tracing. Alternatively, two photographs may be taken, one with the specimen flat and the other with it set to show the 'squamous edge' (fig 2).

Histological technique is important. Formol/corrosive solution is the fixative of choice as this, in addition to its other merits, hardens the tissue adequately to permit the cutting of thin flat blocks (about 2 mm thick). The use of a sharp knife is of prime practical importance to avoid distortion of the tissue blocks. If the block is distorted or the face of

<sup>1</sup>The photographs in fig 2 were taken with a Zeiss Tessovar Camera fitted with a Polaroid Back. A Polaroid MP-3 Camera has been used on occasions but the lower-priced Polaroid CU-5 Close-up Land Camera (capable of photographs at 1 : 1 or 2 : 1) is adequate for the purpose.



**Fig 2** *The composite report: The cone biopsy photographed flat and inclined to show a 'Schiller negative' area at left of specimen. In practice, blocks are not marked on the photograph individually as they are cut but segments are selected and marked, the respective number of blocks cut from each being noted. The cut surfaces (hatched areas) made by the histologist on opening the cone biopsy are indicated.*

*'Inadequate excision', suggested by the iodine non-staining area, is corroborated by the histological findings. In this particular case invasive carcinoma was not present.*

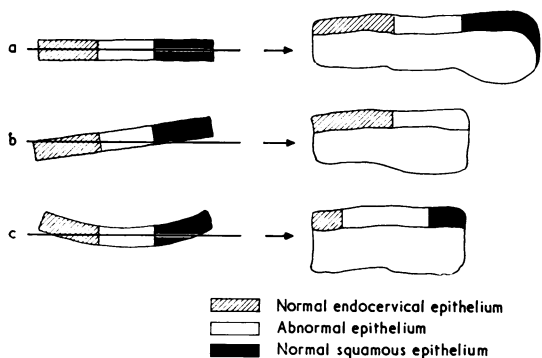


Fig 3 Histological technique is important. The tissue block should be flat and cut with its face set parallel to the cutting edge of the microtome knife. The full extent of the epithelial surface will then be represented in the histological section (a). If the face of the block is not set parallel to the cutting edge of the microtome knife (b), or if the tissue block is distorted (c), the resulting histological sections will not accurately demonstrate the extent and distribution of the pathological changes.

the block is not set parallel to the edge of the microtome knife during section-cutting, the resulting stained histology section will not include the full extent of the epithelial surface and this could lead to misinterpretation of the histological changes (fig 3). A prerequisite of this sequence is efficient histological section-cutting. In our experience, one section per block (preferably ribboned) is generally adequate. This does not impose an undue burden on the technical staff, and this extent of histological examination we consider necessary for provision of an adequate report and, in addition, view it as the reasonable entitlement of a woman who has undergone conization, either as a diagnostic procedure or as the definitive treatment of a cervical lesion.

The merits claimed for this routine and composite report are:

- 1 It provides a photographic record of the size and shape of the cone-biopsy specimen which may be 'adequate', 'inadequate', fragmented or of irregular shape, factors which determine how the histological blocks should be selected and cut.
- 2 The histologist's interpretation of the sections is assisted by referral to the photographic record of their orientation, without which a full appreciation of the distribution and extent of a lesion can be difficult or impossible.
- 3 It displays to the surgeon the topographical distribution of the cervical lesion, enables comparison of this to be made with the result of the Schiller iodine test, and shows his line of excision in relation to the field of abnormal epithelium, consideration of which may influence his judgment on subsequent treatment and follow-up.
- 4 With a recent upsurge of gynaecological interest in the role of colposcopy in the diagnosis and management of cervical epithelial abnormalities, the composite histology report described may contribute to stimulating this interest, and it enables the gynaecologist to correlate his colposcopic assessment of a lesion with its histological counterpart.

We wish to thank our gynaecological colleagues and Mr. R. G. W. Taylor, chief cytology technician, for their helpful cooperation in many ways, and Mrs. E. Weston for secretarial assistance and the able way she compiled the final 'composite report'.

We are also indebted to Polaroid (UK) Limited for meeting the cost of the colour plate.

#### Reference

Sanerkin, N. G. and Fraser, J. M. R. (1975). A technique for the orientation of blocks and sections from unbisected cervical cones. *J. clin. Path.*, **28**, 202-203.