


W1  
J05896

READING  
ROOM


# Journal of Clinical Pathology

*The Journal of the Association of Clinical Pathologists*

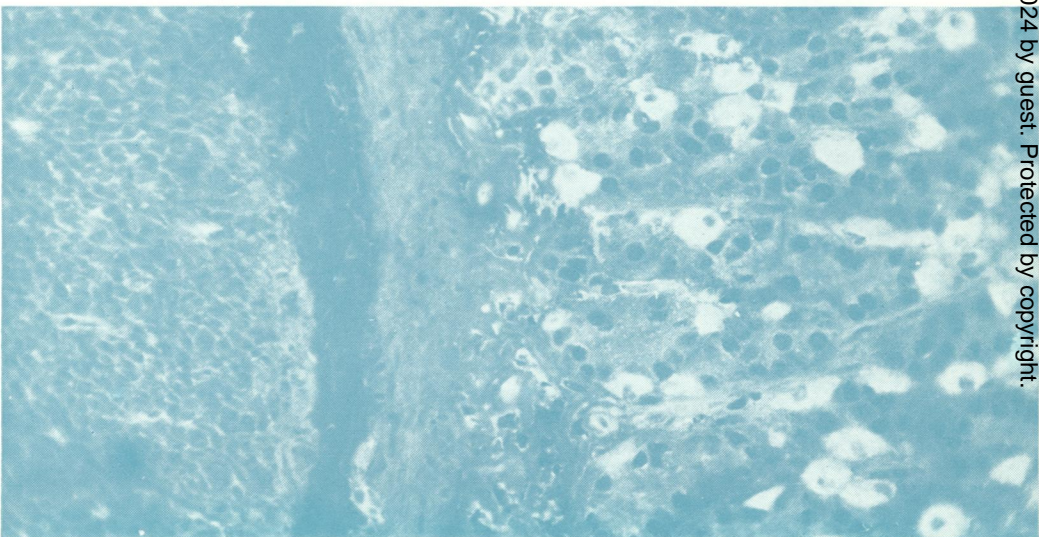


Vol. 30, No. 4, April 1977

(a)



(b)



*Classical immunofluorescent heterophile antibody*  
(a) Rat heart interstitium.  
(b) Rat gastric parietal cells. See Fig. 1, pages 300 and 301.