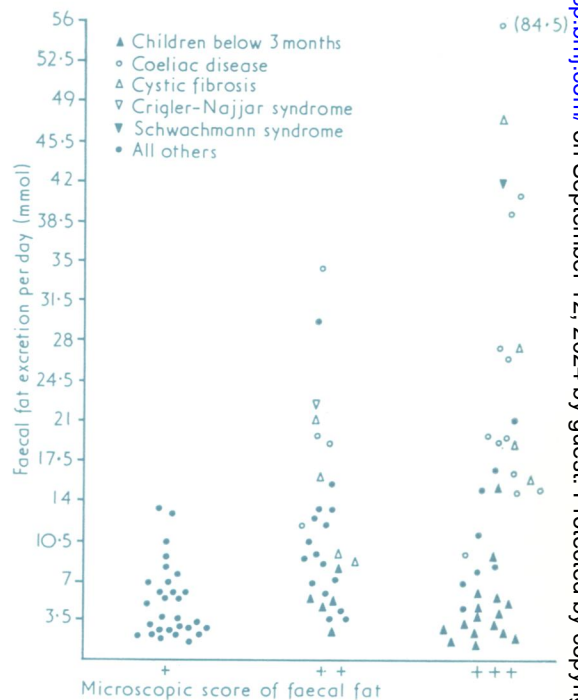
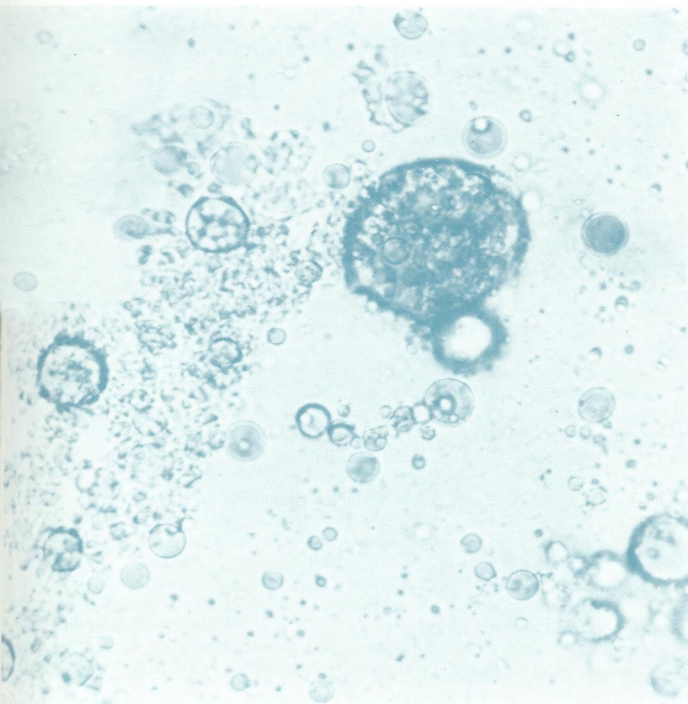



W/ 105896

Journal of Clinical Pathology

The Journal of the Association of Clinical Pathologists

Vol. 30, No. 8, August 1977



Left Photomicrograph of stool showing microscopy score of 3+ for faecal fat ($\times 290$). Right Comparison of quantitative estimation of faecal fat with microscopy in 100 children of all ages according to final diagnosis. See Figs. 1 and 3, pages 750 and 751.