

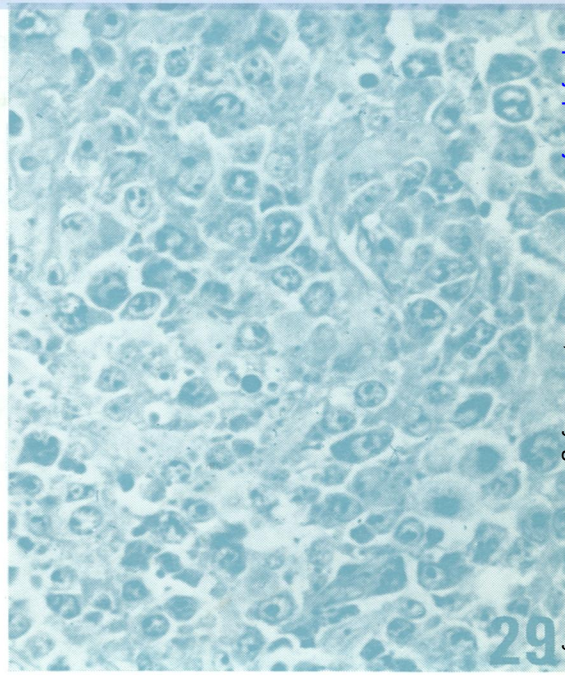
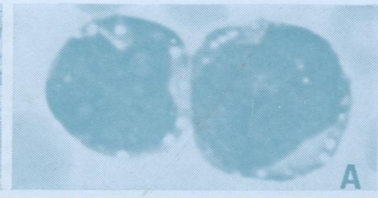
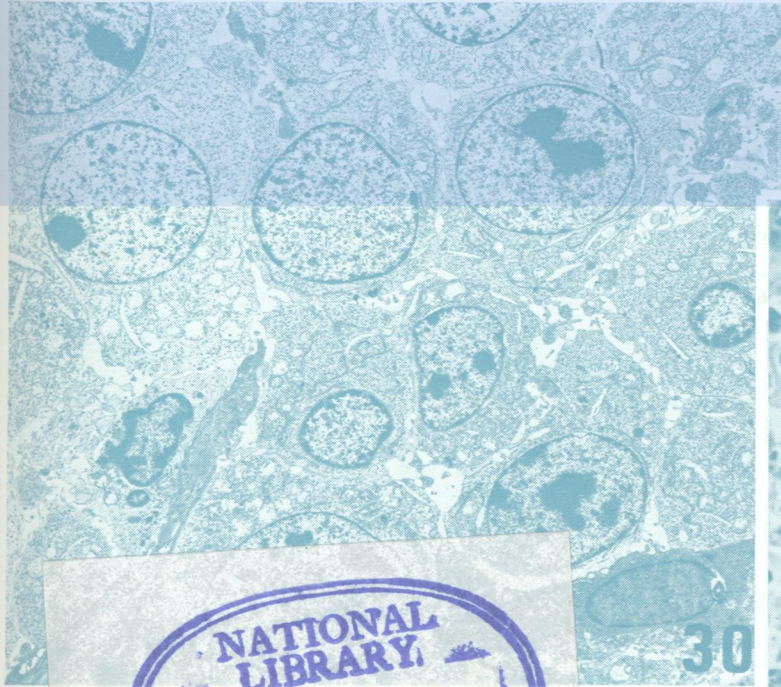
W1
J05896

DR

Journal of Clinical Pathology

The Journal of the Association of Clinical Pathologists

Vol. 31, No. 11, November 1978



NATIONAL LIBRARY
FEB 13 1979
OF MEDICINE

(Right) Malignant lymphoma, immunoblastic. Axillary lymph node from 66-year-old man. Diffuse proliferation of large cells with basophilic cytoplasm and large central nucleolus. A few cells reveal plasmacytoid features. (Giemsa $\times 400$) (Left) Malignant lymphoma, immunoblastic. Immunoblasts with oval or round, pale nuclei, prominent nucleoli, and scanty rough endoplasmic reticulum ($\times 4000$). Inset A: malignant lymphoma, immunoblastic, 66-year-old man. PB smear: WBC $56 \times 10^9/l$, circulating immunoblasts 40%. Two immunoblasts (May-Grünwald Giemsa $\times 1000$) See Fig. 29, page 1034 and Fig. 30, page 1038

J Clin Pathol: first published as on 1 November 1978. Downloaded from <http://jcp.bmj.com/> on June 29, 2022 by guest. Protected by copyright.