

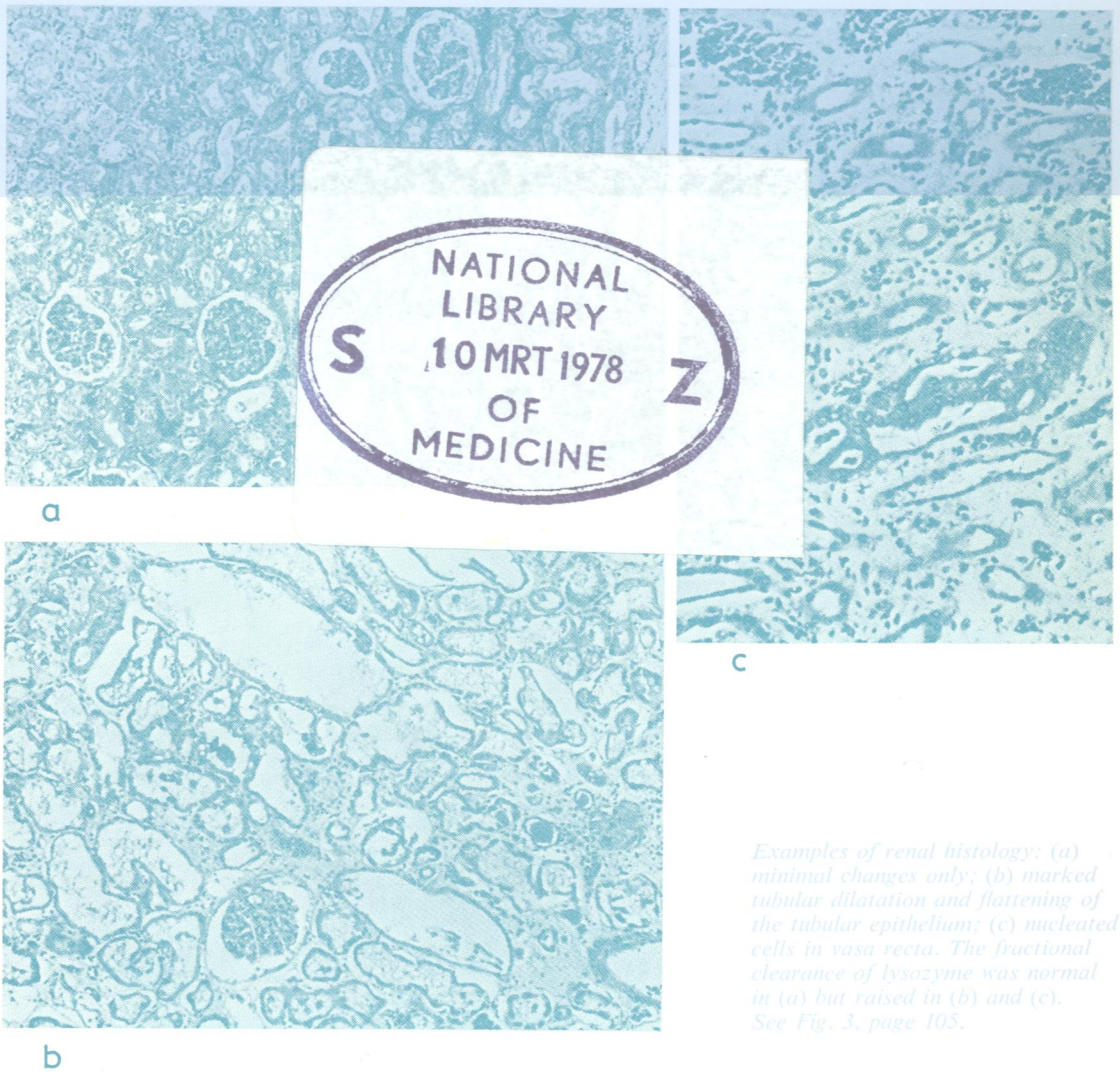
505896

COP72

Journal of Clinical Pathology

The Journal of the Association of Clinical Pathologists

Vol. 31, No. 2, February 1978



Examples of renal histology: (a) minimal changes only; (b) marked tubular dilatation and flattening of the tubular epithelium; (c) nucleated cells in vasa recta. The fractional clearance of lysozyme was normal in (a) but raised in (b) and (c). See Fig. 3, page 105.