

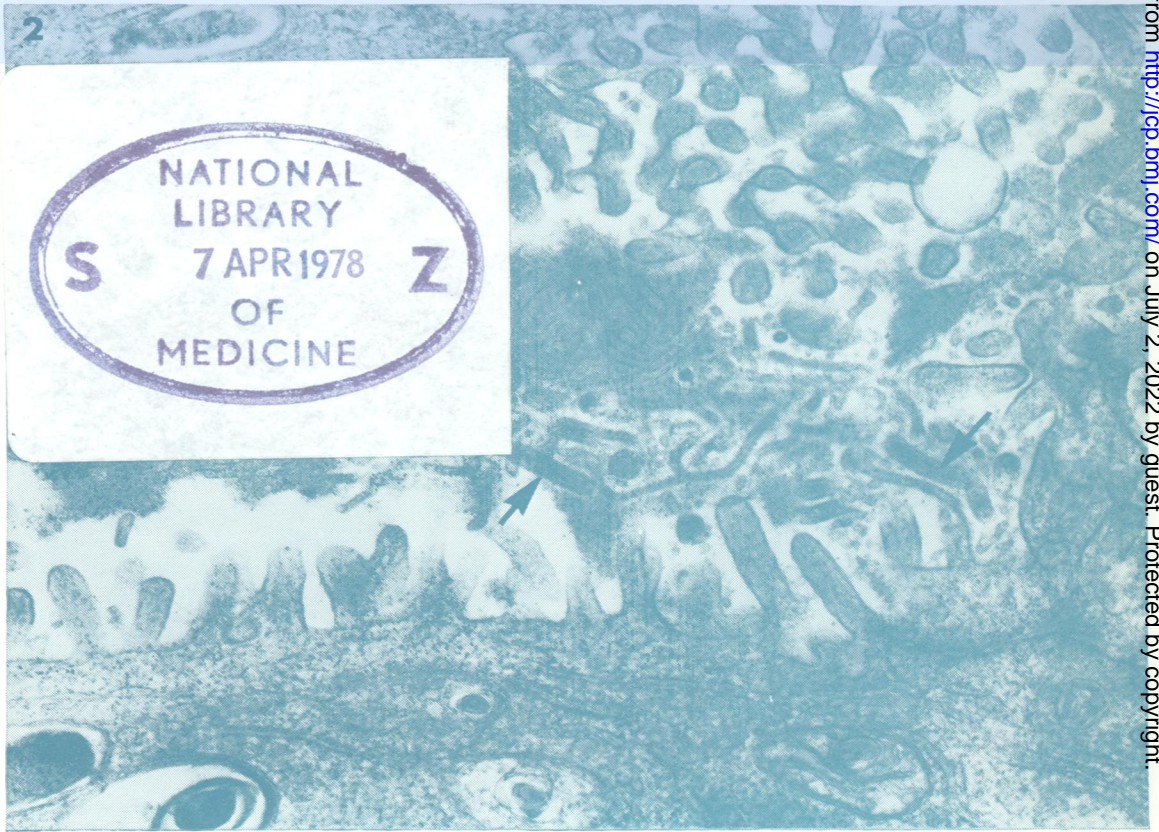
5896

COPY 2

# Journal of Clinical Pathology

The Journal of the Association of Clinical Pathologists

Vol. 31, No. 3, March 1978



*Virus particles extruded into bile canaliculus; note some branched and many incomplete. Two complete virions arrowed. Serrated material lying within the lumen is usually associated with virions. ( $\times 42\ 000$ ). See p. 2, page 203.*

J Clin Pathol: first published as on 1 March 1978. Downloaded from <http://jcp.bmj.com/> on July 2, 2022 by guest. Protected by copyright.