

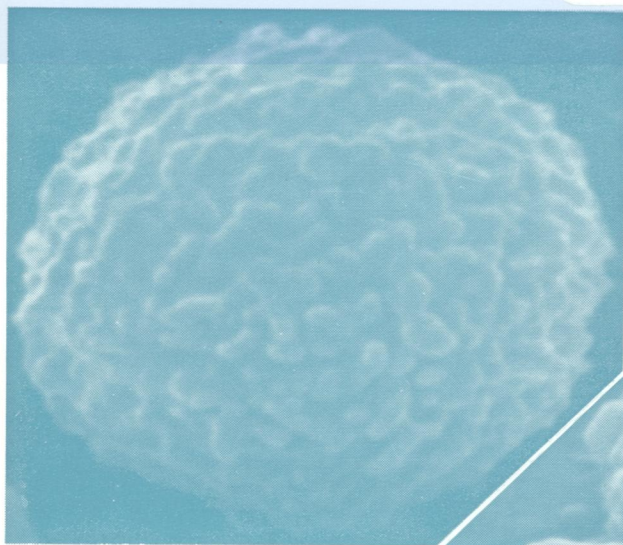
W/1
J0 5896

cop72

Journal of Clinical Pathology

The Journal of the Association of Clinical Pathologists

Vol. 31, No. 4, April 1978



Normal neutrophil, spherical form, showing regular small fine ruffles and occasional poorly defined small, knob-like projections with little space between surface elevations ($\times 11\,400$). See Fig. 1, page 303.

Two neutrophils in the lazy leucocyte syndrome. The upper, an amoeboid form, shows loss of both fine and large filmy ruffles with, instead, small, irregularly distributed, knob-like projections and occasional poorly developed ruffles with extensive featureless areas between. The lower shows coarsening of the ruffled pattern ($\times 11\,400$). See Fig. 4, page 304.

