

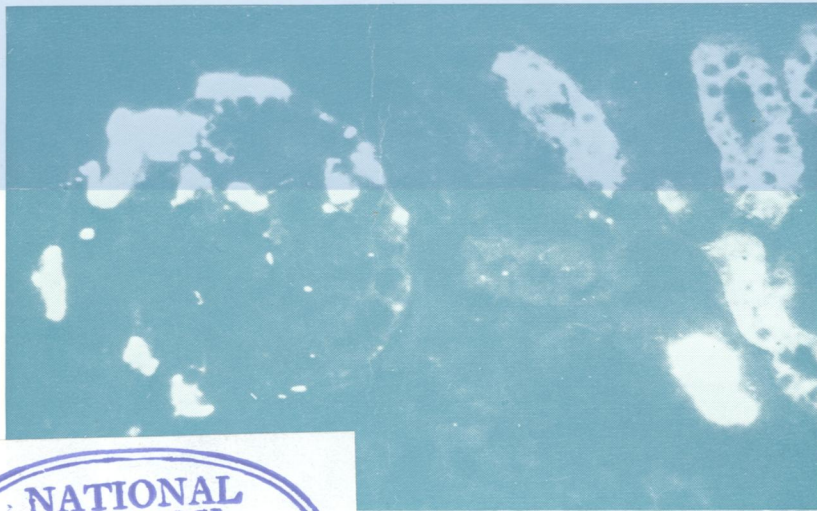W1
Jo 5896

DR

Journal of Clinical Pathology

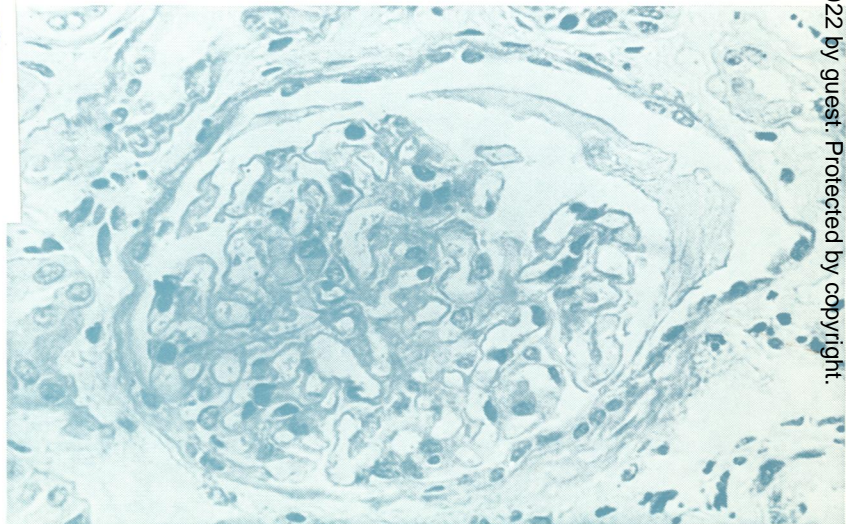
The Journal of the Association of Clinical Pathologists

Vol. 31, No. 7, July 1978



Tamm-Horsfall protein stains brightly in tubular casts as well as in distal convoluted tubules. Prominent aggregates in capsular space and between glomerular tufts (case 7). $\times 150$. See Fig. 2, p. 621

NATIONAL LIBRARY
AUG 25 1978
OF MEDICINE



Glomerulus showing irregular crescent of proteinaceous material in capsular space (case 1). Periodic acid Schiff $\times 420$. See Fig. 5, p. 623