

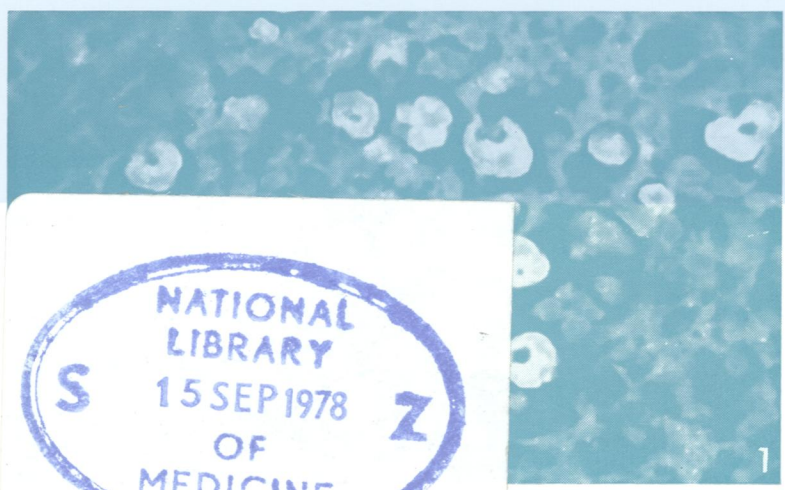
W/1
JO 5896

COP72

Journal of Clinical Pathology

The Journal of the Association of Clinical Pathologists

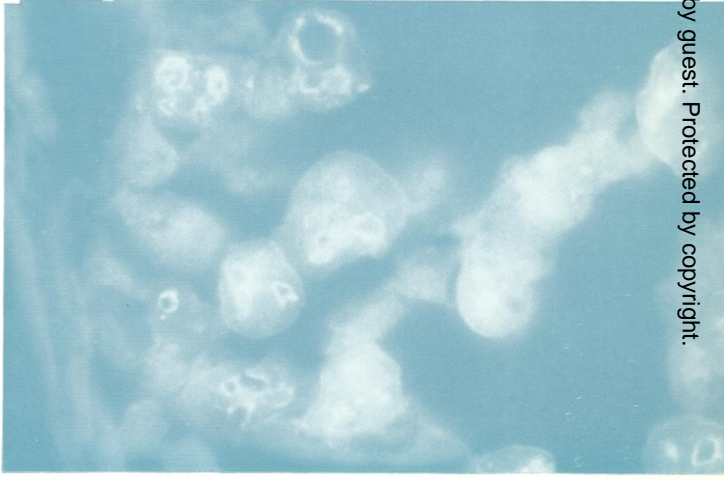
Vol. 31, No. 8, August 1978



NATIONAL LIBRARY OF MEDICINE
 15 SEP 1978
 S Z

Bright fluorescent staining of amoebae in the brain sections with anti-*A. culbertsoni* plasma membrane antiserum (dilution 1:32), $\times 750$. See Fig. 1, p. 719.

Indirect immunofluorescent staining of brain sections with anti-*A. culbertsoni* plasma membrane antiserum (dilution 1:256). The fluorescence appears mainly on the membranes of the cytoplasmic vacuoles of the amoebae. $\times 1250$. See Fig. 2, p. 719.



J Clin Pathol: first published as on 1 August 1978. Downloaded from <http://jcp.bmj.com/> on February 22, 2024 by guest. Protected by copyright.