

Letter to the Editor

Buffy-coat smear of bloodstained aspirate and intraperitoneal bleeding

Abdominal paracentesis is frequently the best way to diagnose intraperitoneal bleeding. When bloodstained aspirate is obtained it may still be very difficult to determine whether the blood is from traumatic bleeding during the procedure, from large blood vessels, or from blood already present before the procedure.

Recently we encountered a patient who was suspected of having intraperitoneal bleeding due to rupture of a liver adenoma. The bloodstained aspirate obtained by abdominal paracentesis had a haematocrit approximately that of the peripheral blood. The bloodstained aspirate did not readily coagulate but clotting was also prolonged in the venous blood because of disseminated intravascular coagulation. The possibility that the blood came from a large vein or was induced by bleeding during the procedure could not easily be ruled out. We used a simple method of buffy-coat examination of aspirate.

A heparinised capillary tube was filled with bloodstained aspirate immediately after paracentesis and centrifuged after one end had been sealed. The tube was then broken at the buffy-coat

area into two pieces. The smear from the buffy-coat was prepared using either microslides or cover slides and stained with Wright stain. Many macrophages of different sizes and degrees of erythrophagocytosis were observed (Figure).

The number of macrophages in the peritoneal cavity of animals increases significantly after the local injection of many different stimulants (Carr, 1973); intraperitoneal bleeding produces a similar response. Phagocytosis of these 'foreign' red cells also takes place. The abundance of macrophages and marked erythrophagocytosis indicate that there had been blood in the peritoneal cavity for some time. Surgery performed later confirmed the diagnosis of intraperitoneal bleeding. This simple method of examination by buffy-coat smear of bloodstained aspirate helps in the diagnosis of intra-abdominal bleeding.

J.-Y. CHU

Department of Pediatrics,
St Louis University School of
Medicine and Cardinal Glennon
Memorial Hospital for Children,
St Louis, Missouri, USA

Reference

Carr, I. (1973). *The Macrophage: A Review of Ultrastructure and Function*. Academic Press, London.

Book reviews

Systemic Pathology. Volume 2, 2nd edition. By 38 authors. Edited by W. St. C. Symmers. (Pp. 564; illustrated; £29.50.) Edinburgh, London, New York: Churchill Livingstone. 1978.

The first volume of the second edition of *Systemic Pathology* told us that the next would cover the blood, lymphoreticular system, thymus, gastrointestinal canal, and liver. In the event we get only the first three and a 50% price rise, with gut and liver to follow.

The 75 pages on the blood will not settle the evergreen argument as to whether histopathologists should know more or less haematology, but an opportunity to concentrate on the haematological aspects of morphological disease has not been fully grasped. The thymus is clearly but briefly covered (31 pp), and the 16 pages of text may not be enough to solve a mediastinal problem. But this volume will be judged on the large section on lymphoid diseases written by the editor, and his descriptions of the reactive lymphadenopathies are better than ever. The 100 pages, 350 references, and 90 illustrations devoted to lymphomas will become well-thumbed. The Rappaport, Lukes, and Kiel classifications are set out in detail, but the author does not use any of them and defends the use *pro tem* of the old terms. Rarities such as Burkitt lymphoma and Kaposi's sarcoma are well described in depth but histiocytic, immunoblastic, and undifferentiated lymphomas are dealt with in four pages between them. Despite a slight lack of balance, this is far the best book for the histopathology of the benign and malignant diseases of the lymphoid system. Forget the price and stretch the budget as pathologists, young and old, green or grey, all need and will use this book.

R. A. B. DRURY

Clinical Laboratory Medicine. Clinical Application of Laboratory Data, 3rd edition. By Richard Ravel (Pp. xii + 531; illustrated; £11.50.) Chicago, London: Year Book Publishers. 1978.

This popular, laboratory-orientated book is now in its third edition, each previous edition having been reprinted on three occasions. There is little doubt that it fulfills a need.

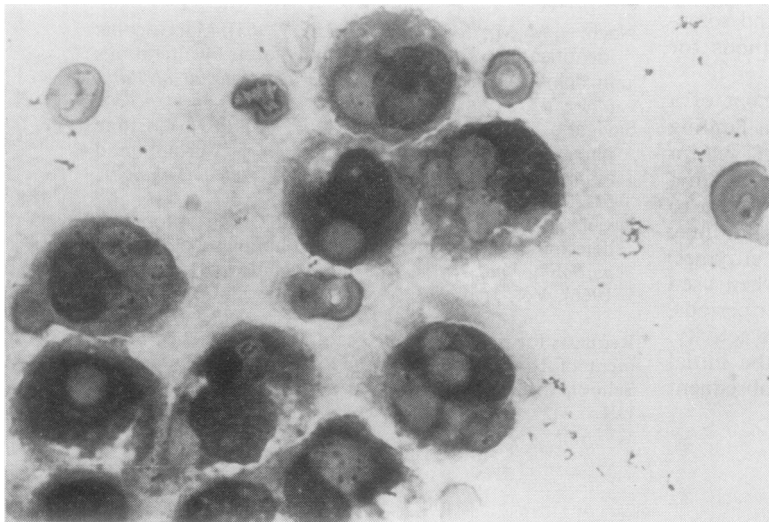


Figure Buffy-coat smear of bloodstained peritoneal aspirate demonstrating erythrophagocytosis.