

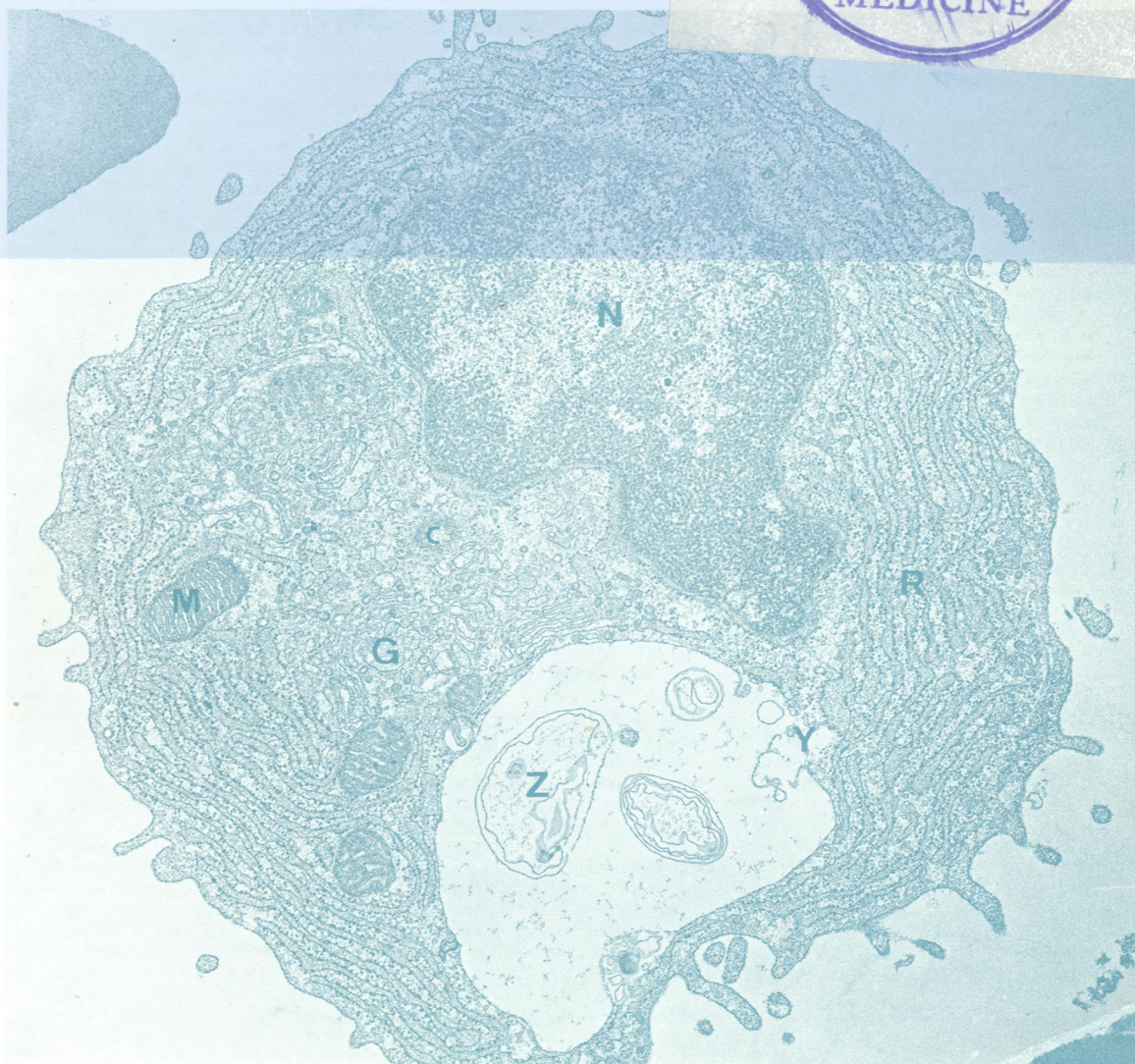

WI  
50  
5'896

DR

# Journal of Clinical Pathology

*The Journal of the Association of Clinical Pathologists*

Vol. 32, No. 4, April 1979



*A plasma cell with a large cytoplasmic vacuole: N = nucleus, y = disrupted membrane, Z = membrane fragments, c = centriole, G = Golgi apparatus, R = rough endoplasmic reticulum, M = mitochondria.  $\times 21\ 230$ . See Fig. 10, page 341.*