


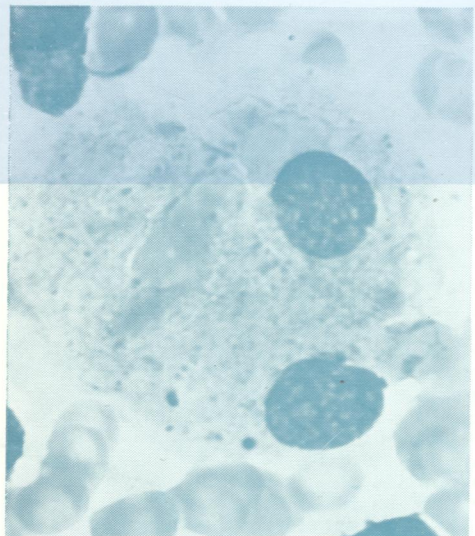

W1
Jo
5896

DR

Journal of Clinical Pathology

The Journal of the Association of Clinical Pathologists

Vol. 32, No. 5, May 1979



(Top left) *Pseudo-Gaucher cell containing phagocytosed cell debris from a patient with aplastic anaemia.*
(Bottom left) *The same field as above showing many rather coarse birefringent crystals.*
(Right) *EM photograph of bundles of microtubules in a blue crystal which would be birefringent. See Figs. 4 and 5, page 422 and Fig. 13, page 426.*