

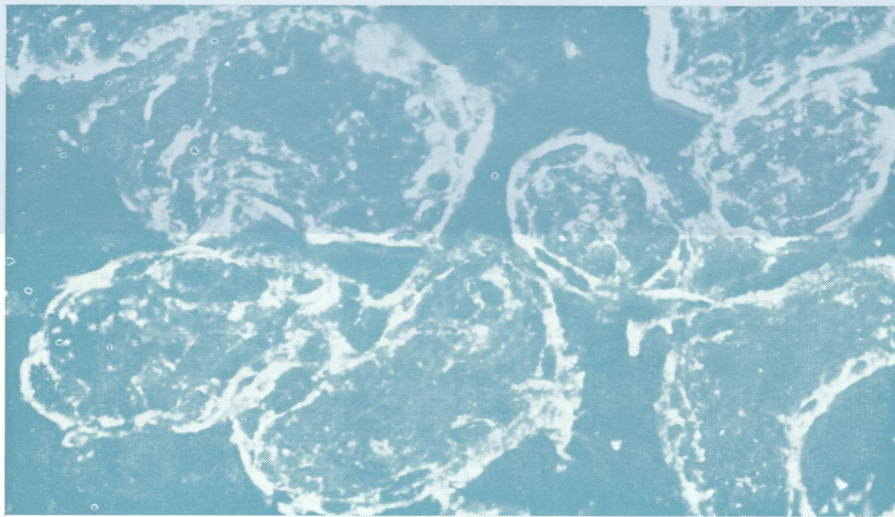
W1  
Jo  
5896

DR

# Journal of Clinical Pathology

*The Journal of the Association of Clinical Pathologists*

Vol. 32, No. 6, June 1979



(Top) Anti-eluate 1-32 fluorescent staining. Trophoblast cells lining normal placental villi.  
(Bottom) Absent fluorescence in the saline control.  $\times 145$ . See Figures a and b, page 525.