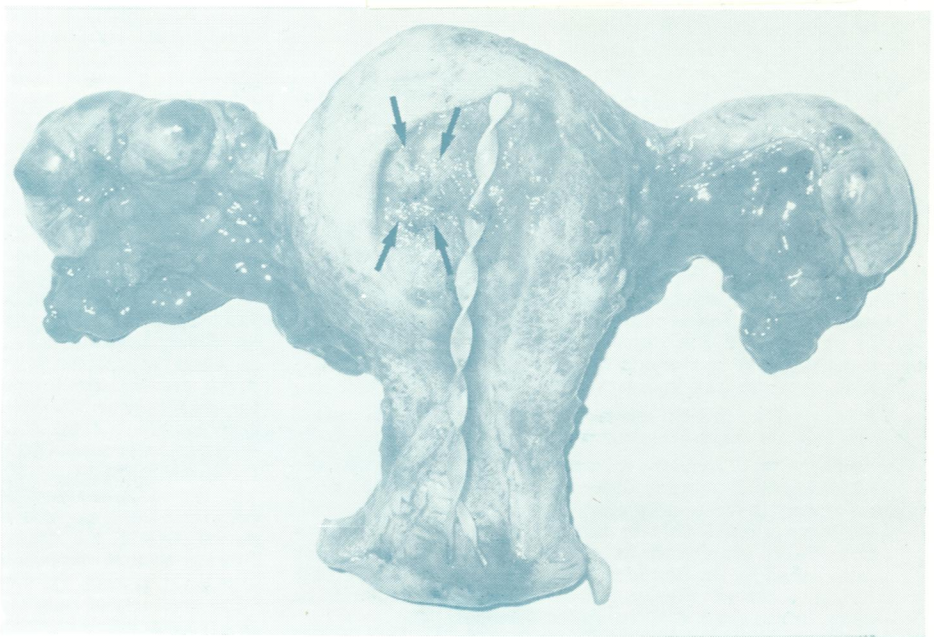




REF  
JG 5896

# Journal of Clinical Pathology

*The Journal of the Association of Clinical Pathologists*

Vol 33, No 1, January 1980



(Left) *The Mi-Mark helix and sound/paddle. (Right) Hysterectomy specimen with helix in situ. Arrows show an area of roughening which proved to be a small carcinoma. See Figs 1 and 8, pages 73 and 78.*