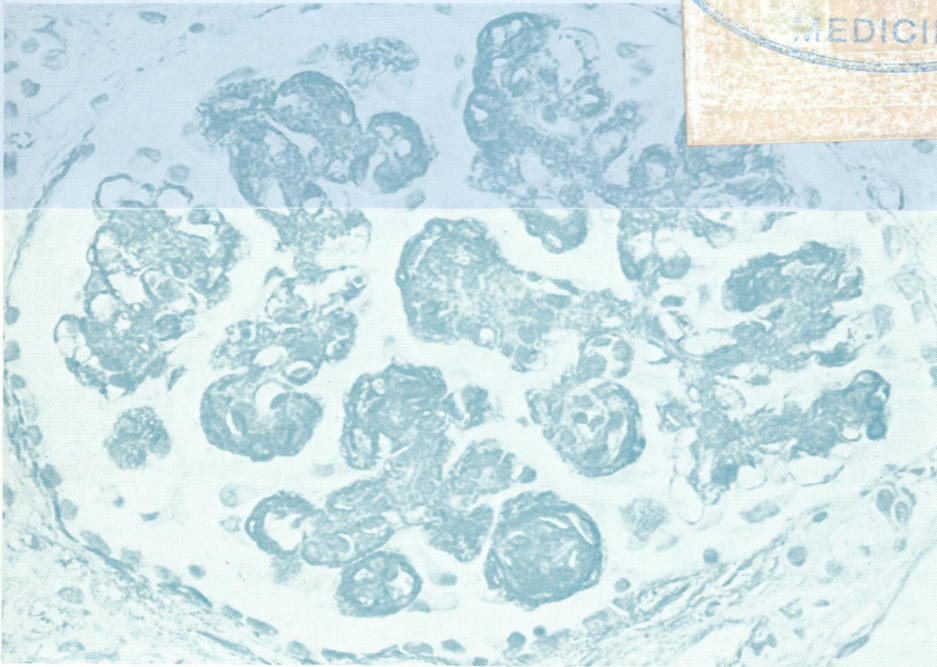



W1
50 5896

Journal of Clinical Pathology

The Journal of the Association of Clinical Pathologists

Vol 33, No 11, November 1980



(Above) Glomerulus in mesangiocapillary glomerulonephritis with increased mesangial and capillary wall staining for fibronectin.
(Below) Glomerulus in membranous glomerulonephritis with increased staining for fibronectin in peripheral capillary walls. See Figs 5 and 6, page 1025.

