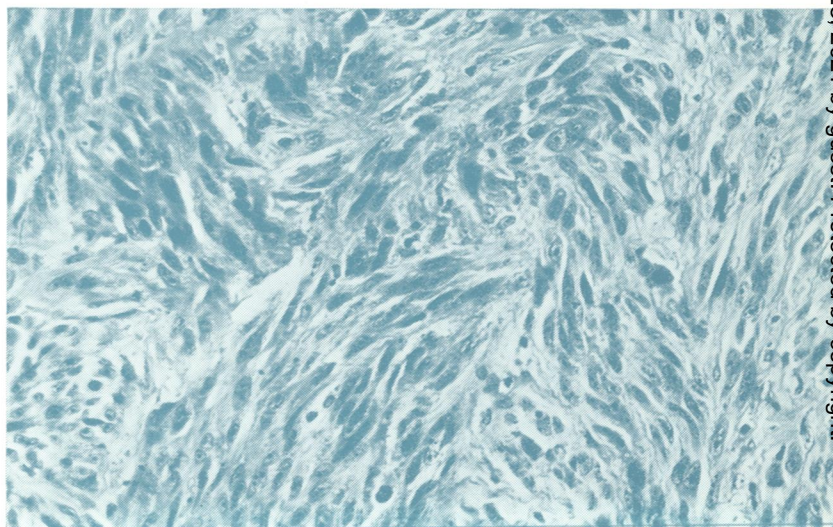

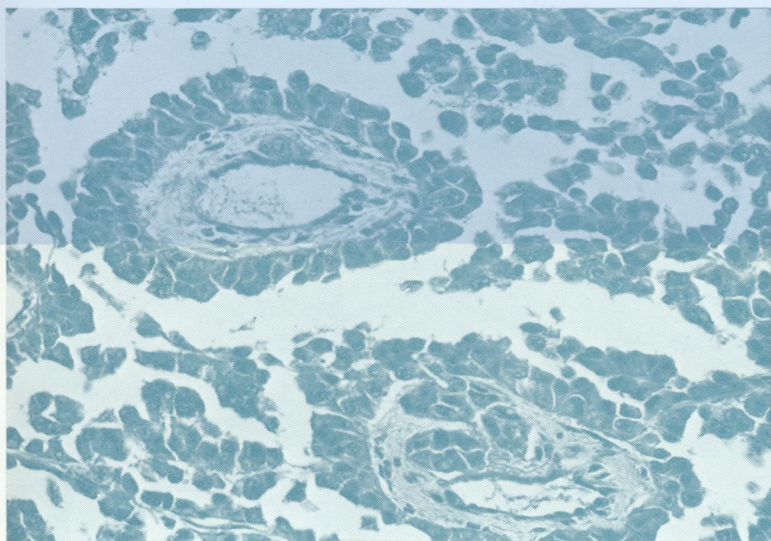


REF
WV
J0 5896

Journal of Clinical Pathology

The Journal of the Association of Clinical Pathologists

Vol. 33, No. 2, February 1980



(Above) A perithelial, pseudopapillary growth pattern of melanoma simulating, for example, renal or thyroid carcinoma. (Right) Achromic spindle cell melanoma has been misinterpreted as fibrosarcoma, fibroxanthoma, and anaplastic squamous cell carcinoma. See Fig 14, page 110 and Fig 15, page 111.