

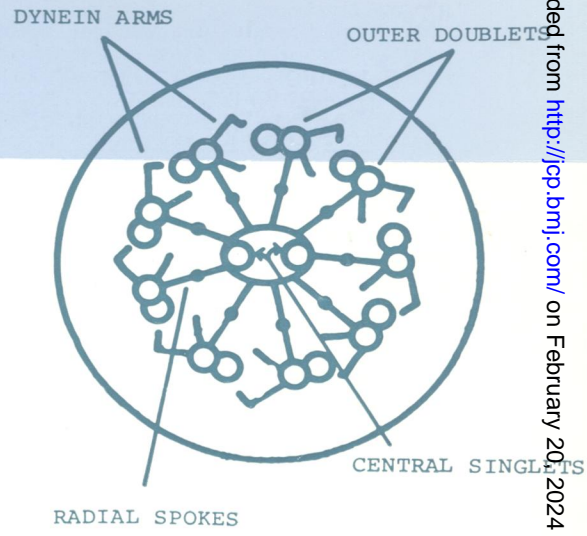
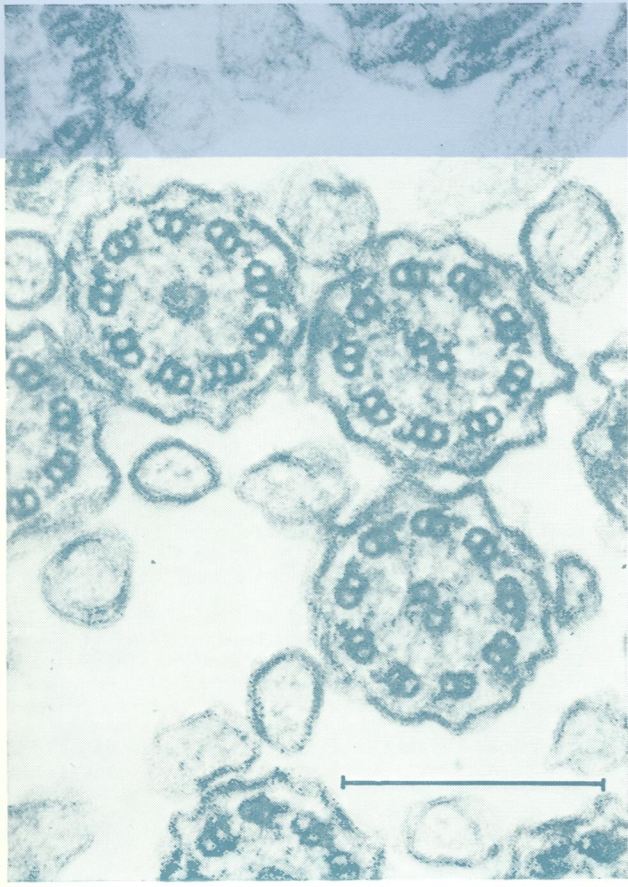

WV/
J05896

COPY 3

Journal of Clinical Pathology

The Journal of the Association of Clinical Pathologists

Vol. 33, No. 4, April 1980



(Left) *Transverse sections of nasal cilia showing normal 9 + 2 and 9 + 0 microtubular arrangements with dynein arms and radial spokes. (Right) Diagram illustrating internal structure of cilia. Bar mark 0.25 μm. See Fig. 2, page 329.*

J Clin Pathol: first published as on 1 April 1980. Downloaded from <http://jcp.bmj.com/> on February 20, 2024 by guest. Protected by copyright.