


W/1
JO 5896

e 3

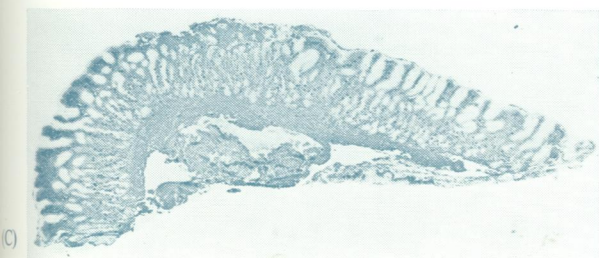
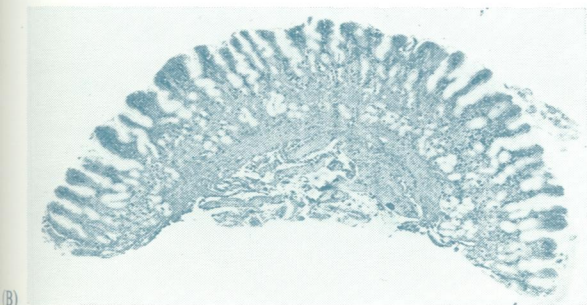
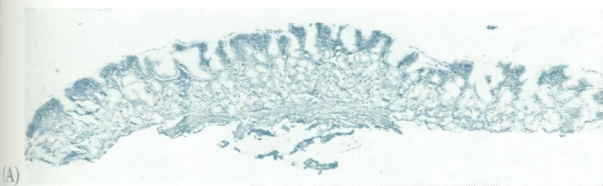
Journal of Clinical Pathology

The Journal of the Association of Clinical Pathologists

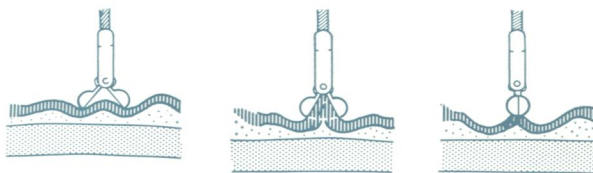
Vol. 33, No. 6, June 1980



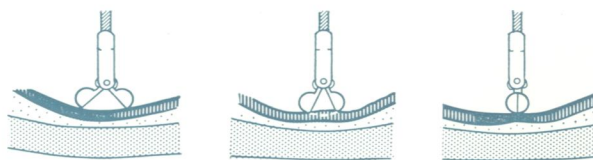
J Clin Pathol: first published as on 1 June 1980. Downloaded from <http://jcp.bmj.com/> on October 24, 2021 by guest. Protected by copyright.



(Left) Examples are shown of biopsy specimens of different shapes: (A) flat specimen; (B) slightly curved specimen; (C) a specimen of complex shape, consisting of a flat part and a curved part (A + B).
(Below) When the stomach is allowed to relax, the antral mucosa becomes lax, resulting in a biopsy specimen consisting of the full thickness of the mucosa. When the stomach is distended with air, the mucosa becomes taut and the biopsy specimen is likely to be superficial. See Figs. 1 and 3, page 514.



MUCOSA LAX



MUCOSA STRETCHED