

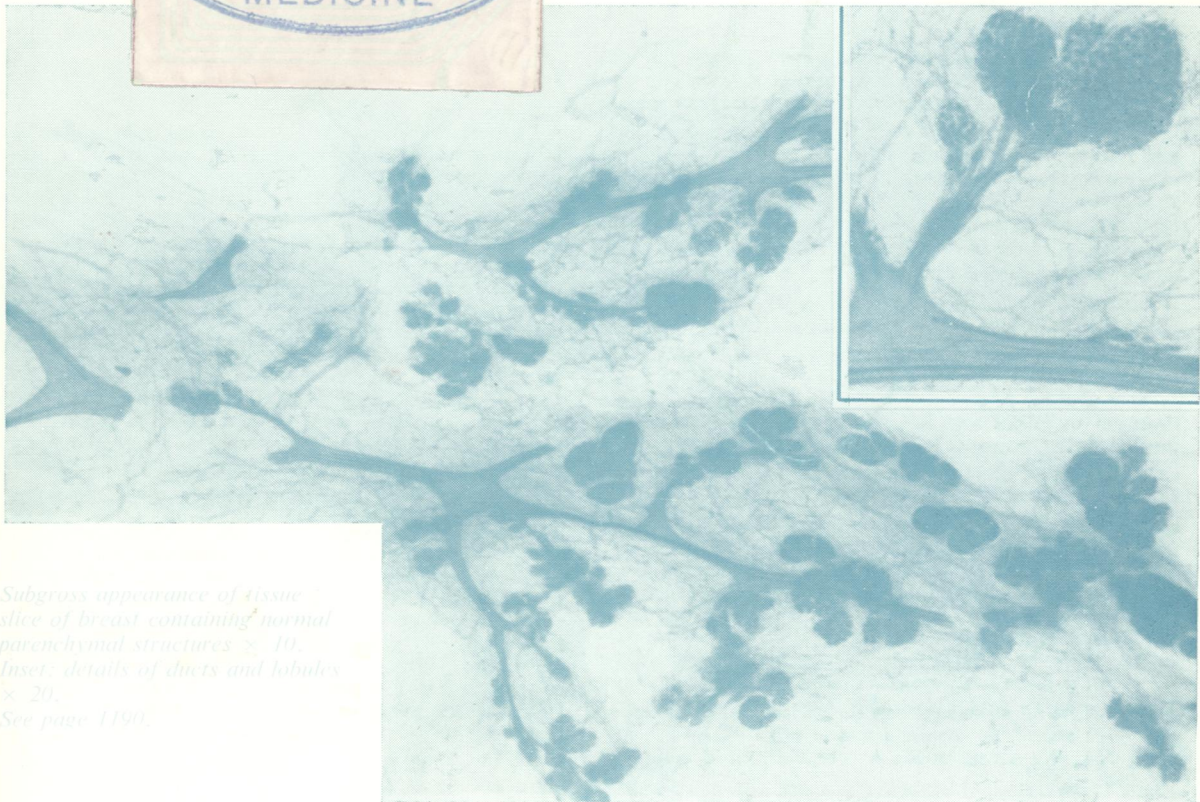

REF  
WI  
to 58 96

C.2

# Journal of Clinical Pathology

*The Journal of the Association of Clinical Pathologists*

Vol 34, No 10, October 1981



*Subgross appearance of tissue slice of breast containing normal parenchymal structures  $\times 10$ .  
Inset: details of ducts and lobules  $\times 20$ .  
See page 1190.*