

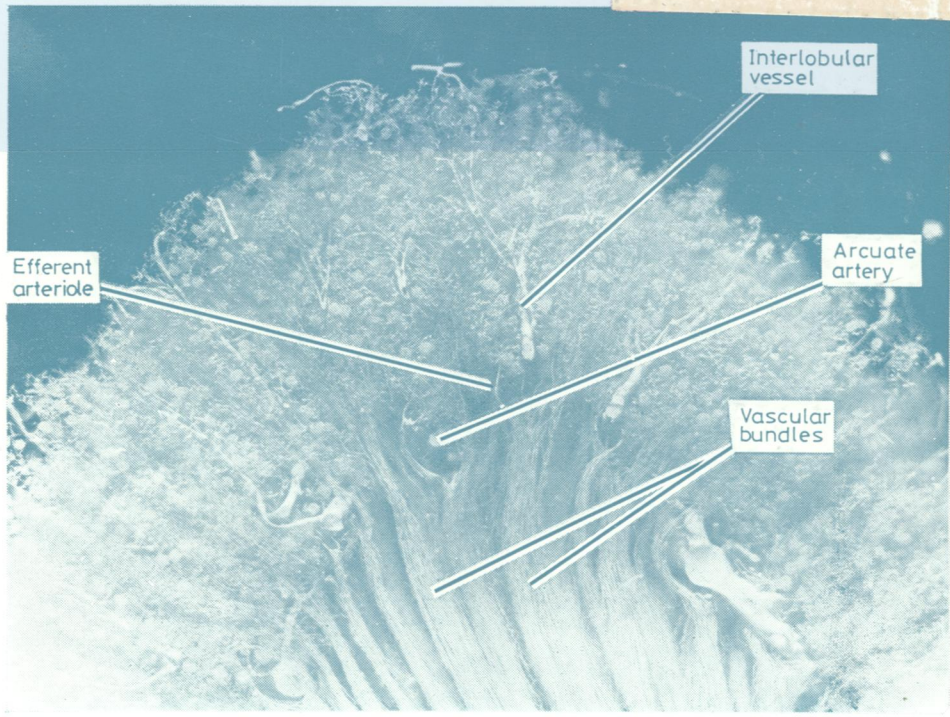

W1  
JO 5896

e 2

# Journal of Clinical Pathology

*The Journal of the Association of Clinical Pathologists*

Vol 34, No 11, November 1981



*Human kidney, Microoil injection. Only the descending vasa recta have been injected, the ascending vasa recta remaining unfilled. See Fig 1, page 1201.*