

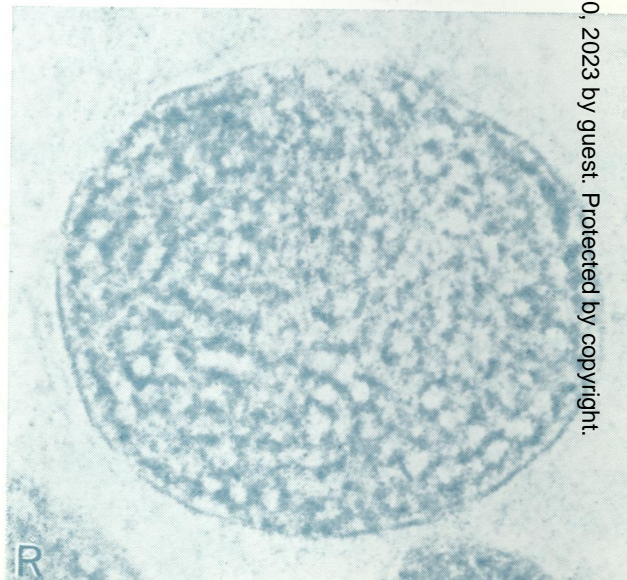

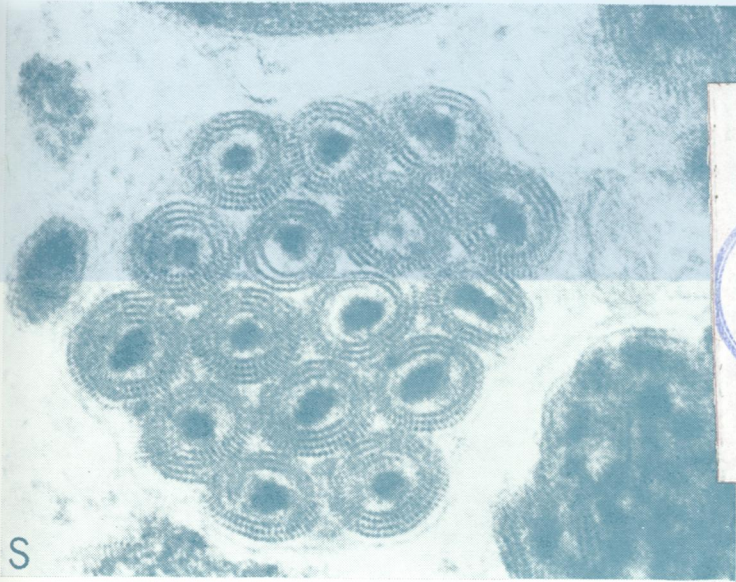
REF
W1
J0 5896

C2

Journal of Clinical Pathology

The Journal of the Association of Clinical Pathologists

Vol 34, No 12, December 1981



...erent types of intracytoplasmic granules in mast...
... S = scrolls, R = reticular. See page 1336.