

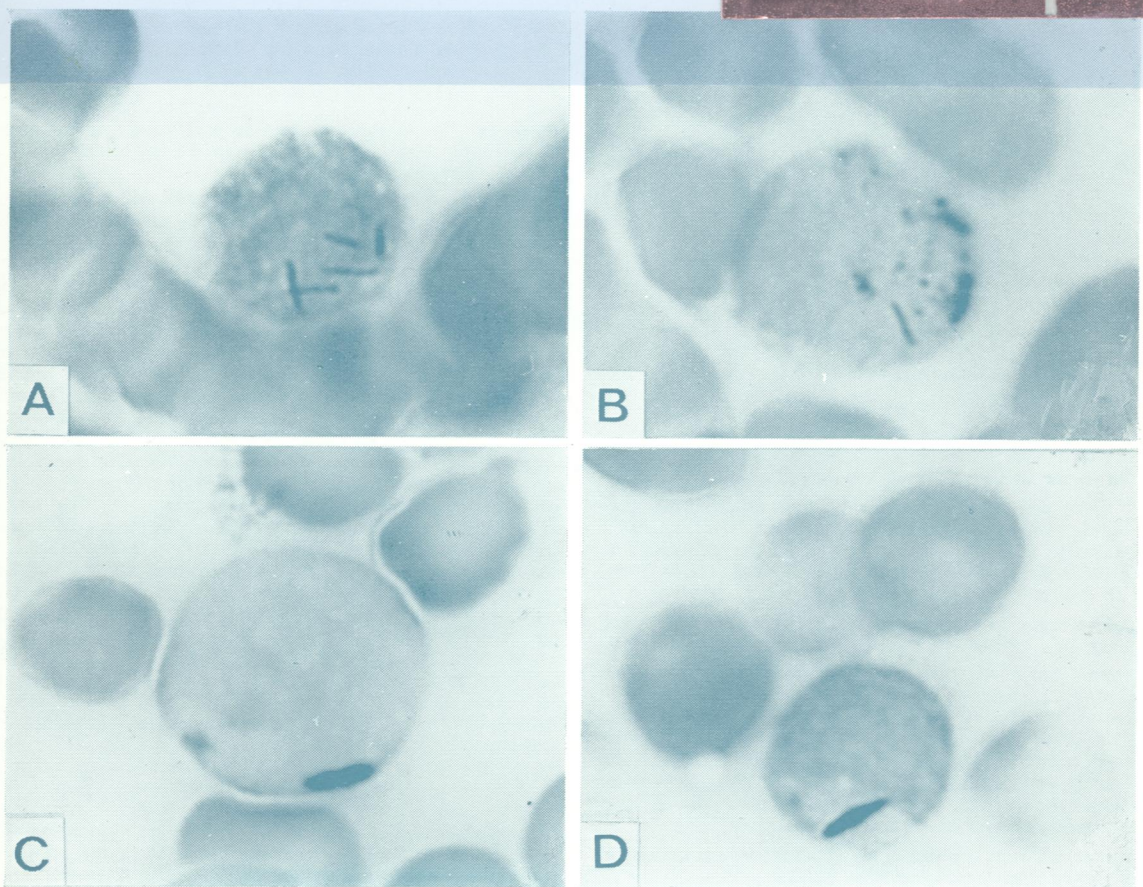

REF
W/1
JO 5896

C12

Journal of Clinical Pathology

The Journal of the Association of Clinical Pathologists

Vol 34, No 2, February 1981



Blast cells of AML cases showing Phi bodies (A, B) or Auer rods (C, D). Phi bodies were seen as thin, sometimes multiple (A), rods, while Auer rods were often single and thicker (C, D) than Phi bodies. (Peroxidase reaction with DAB $\times 1400$). See Figure, page 154.