

REF
WI
5896

C.2

Journal of Clinical Pathology

The Journal of the Association of Clinical Pathologists

Vol 34, No 6, June 1981

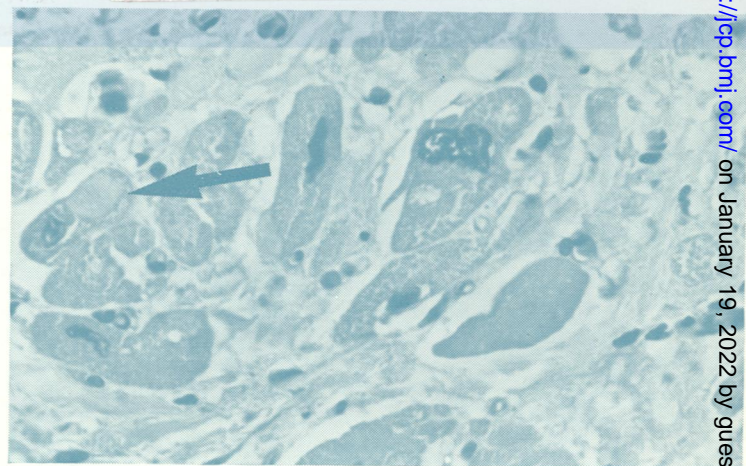
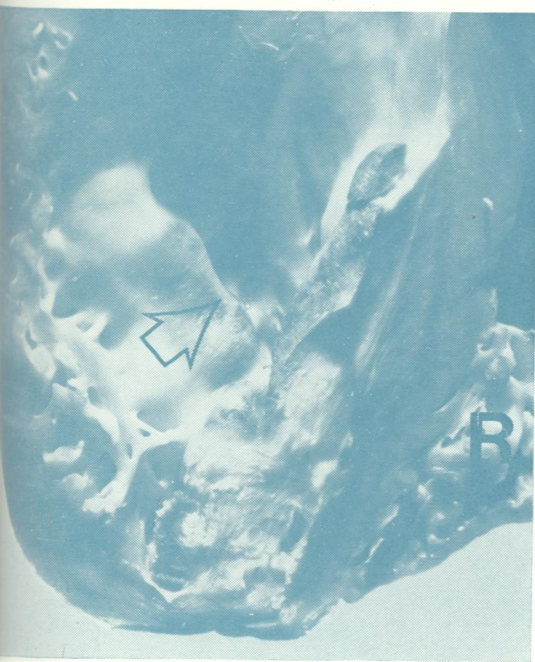


Fig. 2
Adriamycin toxicity. See pages 603-4.
Fig. 1 Note the dense fibrosis affecting the trabeculae carneae of both ventricles, and the sharp upper edge of the lesion in the left ventricle.
Fig. 2 There are many degenerated fibres with interstitial fibrosis. Note the irregularity of the nuclei and the vacuolation of the myocardial fibres.