

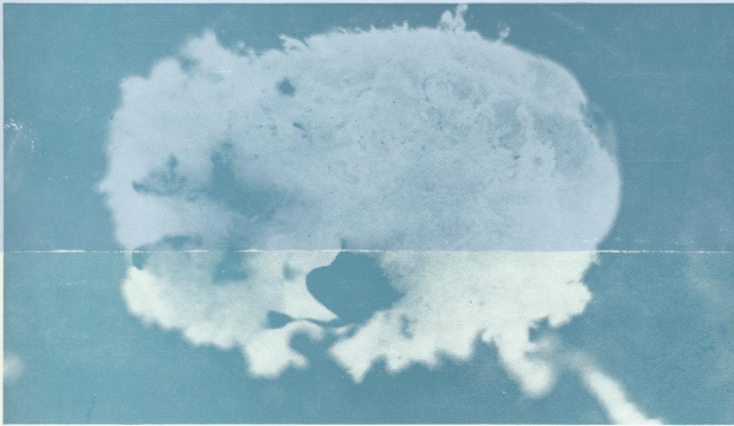
REF
W/1
J0 5896

C-2

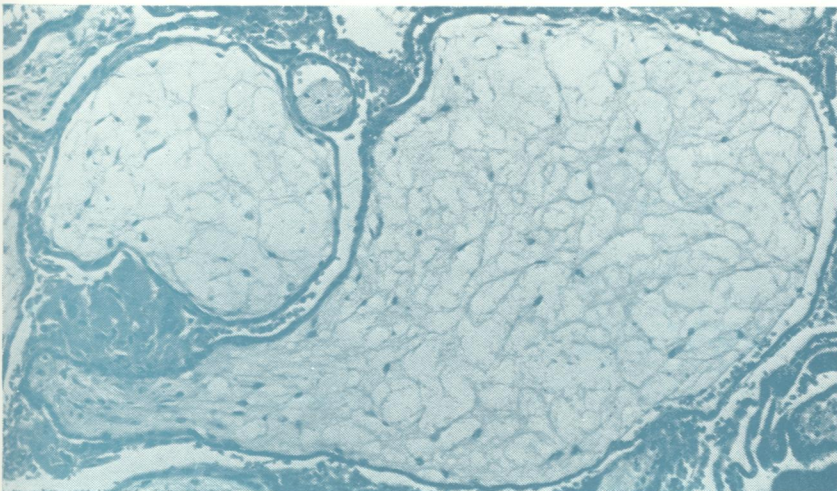
Journal of Clinical Pathology

The Journal of the Association of Clinical Pathologists

Vol 34, No 8, August 1981



(Above) *Blighted ovum aborted at 10 wk. Intact sac 2cm in diameter with no embryo.*
(Below) *Blighted ovum. Villi showing microscopic hydatidiform change. Haematoxylin and eosin $\times 166$.*
See Figs 2 and 3, page 822



NATIONAL
LIBRARY
13 OCT 1981
OF
MEDICINE