

normal level of up to 0.6 even only one year after insertion, the erythrocyte sedimentation rate was also raised. In some cases however, the antibody response may not be quite so pronounced, and here a preoperative serum sample should be examined, so that the two values may be compared. Had samples of serum been taken more frequently in the immediate postoperative period an earlier diagnosis could perhaps have been made. In cases of infection the detection of increased antibody concentrations as soon as possible after the total hip replacement operation may mean that appropriate treatment can be started, thereby increasing the likelihood of successfully salvaging the prosthesis.

We wish to thank the surgeons at the Royal National Orthopaedic Hospital whose patients were included in this study.

S BARSHAM
R BAYSTON

Department of Paediatric Surgery,
Institute of Child Health,
London WC1

SY ALI

Department of Experimental Pathology,
Institute of Orthopaedics,
Royal National Orthopaedic Hospital,
Stanmore,
Middlesex

References

- Ring PA. Total replacement of the hip joint. A review of a thousand operations. *J Bone Joint Surg* 1974; **56 B**:44-58.
- Wilson PD, Amstutz HC, Czerniecki A, Salvati EA, Mendes DG. Total hip replacement with fixation by acrylic cement. A preliminary study of 100 consecutive McKee-Farrar prosthetic replacements. *J Bone Joint Surg* 1972; **54 A**:207-36.
- Bayston R. Serological investigations in children with colonized Spitz-Holter valves. *J Clin Pathol* 1972; **25**:718-20.
- Bayston R. Serological surveillance of children with CSF shunting devices. *Dev Med Child Neurol* 1975; **17**(suppl 35) 104-10.
- Tuazon CU, Sheagren JN. Teichoic acid antibodies in the diagnosis of serious infections with *Staphylococcus aureus*. *Ann Intern Med* 1976; **84**:543-6.
- Wheat LJ, Kohler RB, White A. Solid-phase radioimmunoassay of immunoglobulin G *Staphylococcus aureus* antibody in serious staphylococcal infection. *Ann Intern Med* 1978; **89**:467-72.
- Losnegard N, Oeding P. Immunochemical studies on polysaccharides from *Staphylococcus epidermidis*. I. Isolation and chemical characterization. *Acta Pathol Microbiol Scand* 1963; **58**:482-92.
- Barsham S. *The antibody response to infection by coagulase negative staphylococci in orthopaedic implants*. London: University of London, PhD Thesis, 1984.
- Engvall E, Perlmann P. Enzyme-linked immunosorbent assay, ELISA. III Quantitation of specific antibodies by enzyme-linked anti-immunoglobulin in antigen coated tubes. *J Immunol* 1972; **109**:129-35.
- Voller A, Bidwell D, Bartlett A. Microplate enzyme immunoassays for the immunodiagnosis of virus infections. In: Rose NR, Friedman H, eds. *Manual of clinical immunology*. 506-512. Washington DC: American Society for Microbiology, 1976:506-12.
- Taylor AG, Fincham WJ, Golding MA, Cook J. Infection of total hip prostheses by *Pseudomonas aeruginosa*: An Immunofluorescence and ELISA study of two cases. *J Clin Pathol* 1979; **32**:61-5.
- Carlsson AS. Erythrocyte sedimentation rate in infected and non-infected total hip arthroplasties. *Acta Orthop Scand* 1978; **49**:287-90.
- Forster IW, Crawford R. Sedimentation rate in infected and uninfected total hip arthroplasty. *Clin Orthop* 1982; **168**:48-52.

Cryopreservation with glycerol during cryostat sectioning for localisation of lymphocytes and accessory cell phenotypic subsets in tissue biopsies

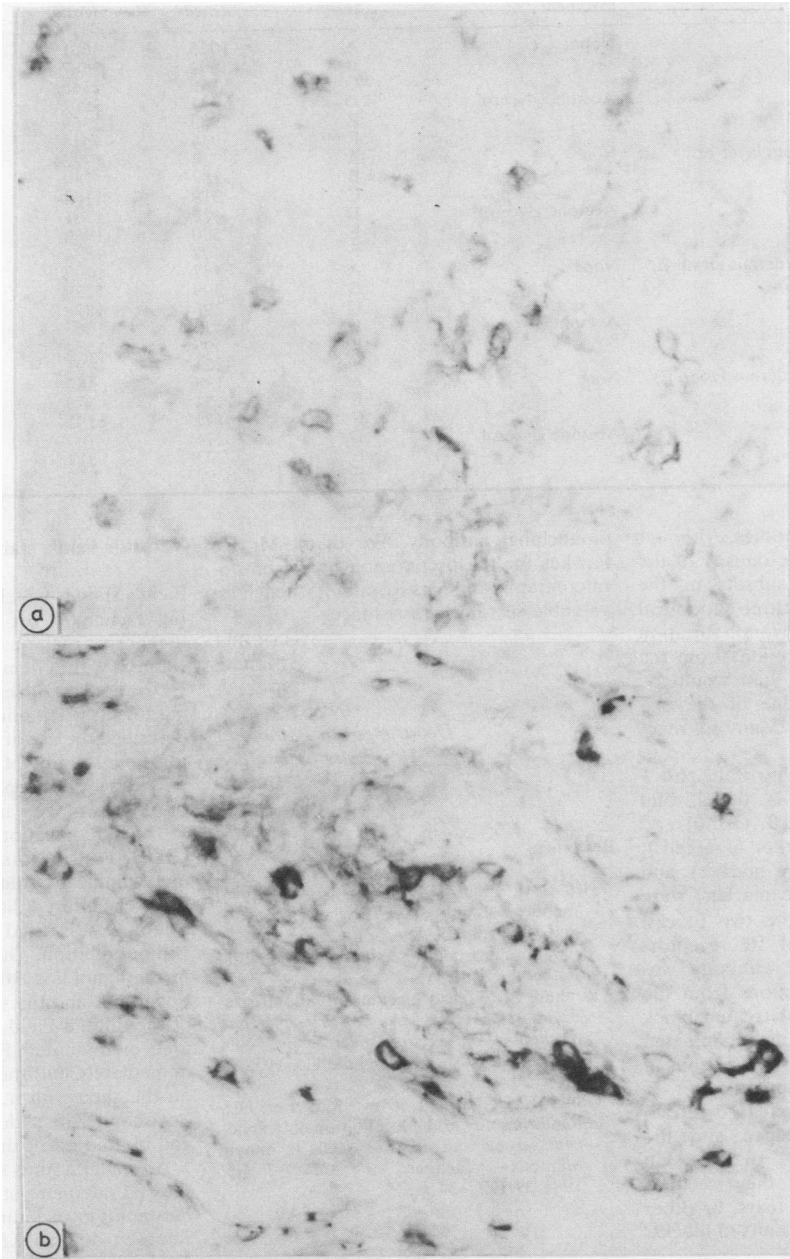
The phenotypic antigens of lymphocytes and accessory cells recognised by monoclonal antibodies are readily destroyed by traditional methods of histological preparation¹ and so the immunoperoxidase method is usually applied to cryostat sections; the sections are often fixed briefly in acetone before staining. We have recently shown that an adaptation of the freeze substitution method² may be applied to the immunocytochemical localisation of lymphocytes and accessory cells in tissue biopsies treated with small quantities of acetone before cryostat sections are cut to improve the contrast of the immunoperoxidase staining without loss of specificity.

Preliminary experiments were made on samples of human tonsil. Small blocks were snap frozen by immersion in liquid nitrogen or an acetone and dry ice slurry. Many of the latter group were accidentally contaminated with acetone; some of the former group were subsequently intentionally contaminated with small amounts of the solvent. The acetone free blocks were readily sectioned in the cryostat, but the acetone treated blocks could not be cut properly. Two types of cryoprotectant solutions were tried: 5, 10, and 20% glycerol and 5% dimethylsulphoxide, all precooled

to 0°C. Acetone contaminated blocks were immersed in these cryoprotectant solutions for 15 to 30 min, placed on metal chucks, refrozen with Cryo Jet spray (Raymond Lamb, London NW10 6JL), and sectioned at 6 µm in a cryostat. Of the cryoprotectants studied, only 5% glycerol consistently allowed the cutting of serial sections; the blocks that had had a greater exposure to acetone required longer immersion in 5% glycerol and sometimes had to be refrozen repeatedly with Cryo Jet spray while in the cryostat. Haematoxylin and eosin stained sections of this tissue did not show any evidence of ice crystal damage and fairly intense immunoperoxidase staining was obtained with monoclonal antibodies to lymphocyte subsets.

A normal volunteer was given an intradermal injection of 0.1 ml of 1/1000 (10 units) purified protein derivative from *Mycobacterium tuberculosis* (Evans Medical Ltd, Middlesex, England) on the volar aspect of the forearm; 48 h later a biopsy was taken from the centre of the delayed hypersensitivity reaction with a 4 mm skin punch (Stiefel Laboratories Ltd, Slough, England). This was bisected, and the halves were frozen as in the pilot experiment. The acetone treated block was exposed to 5% glycerol cryopreservant and refrozen. Serial 6 µm sections were cut from each block. The immunocytochemical staining experiments were made on contiguous groups of sections from the acetone treated and uncontaminated blocks. After treatment with the monoclonal antibody, the section was then treated successively with the Vectastain kit containing biotinylated antimouse immunoglobulin and the three stage reagents, avidin/biotinylated peroxidase (Sera Lab Ltd, Crawley Down, Sussex, UK), and finally a histochemical method was used for generation of the brown reaction product.³ Preliminary examination suggested that the immunocytochemical staining was similar in both sets of sections and so detailed histometric measurements³ were made to determine whether the extra procedure influenced the sensitivity and accuracy of the immunoperoxidase localisation of the two major subpopulations of lymphocytes.

The patterns of staining in acetone and cryopreservant treated sections and the controls stained in the same batch were closely similar; the intensity of staining of T8 cells (Leu 2a, Becton Dickinson) was similar in both blocks, but T4 cells (Leu 3a) were stained more intensely and more crisply in sections from the cryoprotectant treated block. The Table summarises the



Sections from adjacent halves of punch biopsy of Mantoux reaction to intradermal injection of purified protein derivative (PPD) and stained for IL2 receptors with Tac antibody and immunoperoxidase technique. (a) Left untreated block and (b) contaminated block freeze substituted before cryostat sectioning. The preparations were photographed and printed under identical conditions. $\times 330$

Density of T4 and T8 lymphocytes in inflammatory foci and three superficial layers of the intervening dermis (cells/mm²)

Regions of dermis	Section treatment	Set of sections	T8 density	T4 density	T4:T8 ratio
Focal infiltrate	None	A	1025	3601	3.51
		B	804	2687	3.34
		C	790	2368	3.00
	Acetone/glycerol	D	944	3502	3.71
		E	983	3369	3.42
		F	944	4044	4.28
Most superficial 240 µm layer of dermis (zone A)	None	A	314	972	3.10
		B	282	789	2.80
		C	319	1164	3.65
	Acetone/glycerol	D	420	1701	4.05
		E	500	1980	3.96
		F	402	1884	4.69
Next 240 µm layer of dermis (zone B)	None	A	407	1403	3.45
		B	399	1239	3.23
		C	296	1878	6.34
	Acetone/glycerol	D	433	1267	2.93
		E	309	1574	5.09
		F	221	1191	5.41
Next 240 µm layer of dermis (zone C)	None	A	198	484	2.44
		B	154	579	3.76
		C	172	1191	6.92
	Acetone/glycerol	D	274	709	2.59
		E	223	812	3.64
		F	93	611	6.57

results of the histometric studies. Although there are differences in the density of the cells of the two main subsets in the inflammatory foci and the three superficial layers of the dermis, the overall variation between the staining of sections from the two blocks was no more than would be expected from a knowledge of the histopathology of the human Mantoux reaction.³

The distributions of staining of the pan-T markers (Leu 1 and Leu 4), the II2 and transferrin receptors (OKT9, Ortho) and OKT10 (an activation marker of T cells), M1 (Leu M3) (macrophage marker), and of OKT6 (Langerhans' cell marker) were similar in sections from the two blocks. Interestingly the staining of II2 receptors with the Tac monoclonal antibody was much more intense in sections from the acetone and cryopreservant treated block than in sections from the uncontaminated block (Figure). In all studies the sections of the treated blocks were much easier to interpret because of the increased refractivity of the dermal collagen and the presence of faint outlines of the skin appendages. Moreover, the sections showed many fewer folds, tears, or other distortions than those from unfixed blocks.

The cost of the purchase of the commercial monoclonal antibodies was covered by a generous grant from the Wellcome Trust. We are grateful to Dr TA Waldmann of National Institutes of Health, Bethesda, MD, USA for the generous gift of anti-Tac

monoclonal antibody. We thank Mr RS Fawkes for the preparation of the photomicrographs and Mrs Rosalind Mitchell for valuable secretarial assistance.

G COGHILL

JH GIBBS

JG LOWE

J SWANSON BECK

Department of Pathology,
University of Dundee,
Dundee

References

- Hsu S-M, Zhang H-Z, Jaffe ES. Utility of monoclonal antibodies directed against B and T lymphocytes and monocytes in paraffin-embedded sections. *Am J Clin Pathol* 1983;80:415-20.
- Rebhun LI. Freeze-substitution and freeze-drying. In: Hayat MA, ed. *Principles and techniques of electron microscopy*. New York: Van Nostrand Reinhold Co, 1972;3-49.
- Gibbs JH, Ferguson J, Brown RA, et al. Histometric study of the localisation of lymphocyte subsets and accessory cells in human Mantoux reactions. *J Clin Pathol* 1984;37:1227-34.

Versatile field's stain

Field's stain is widely used as a rapid staining technique for thick blood films for diagnosing malaria.¹ Thin films are usually stained with Giemsa stain (Gurr's R66) (BDH, Poole, Dorset), which requires staining for up to 30 minutes. Dacie and Lewin described the use of a modified Field's stain for rapid staining of thin blood films.² Here we describe its application to the staining of other protozoa and also microfilariae.

The modification to the Field stain (BDH, Poole, Dorset) consists of diluting one volume of solution B with four volumes of buffered distilled water at pH 7.2. Solution A is used in its prepared form without dilution. Thin blood films are fixed in methanol for 30 seconds, the alcohol tipped off, and the slide covered with 1 ml of the diluted Field stain B. An equal volume of undiluted Field stain A is added immediately and the two parts mixed well on the slide with a Pasteur pipette. After one minute the slide is rinsed in tap water and blotted or air dried.

All malaria films stained by this method showed adequate staining of all stages of *Plasmodium* including the Schuffner's and James's dots of *P vivax* and *P ovale*. Trypomastigote forms of *Trypanosoma* stained well in thin blood films and also lysed, fixed, and thick blood films. *Leishmania* amastigotes in slit skin smears and bone marrow aspirations stained in a similar manner gave excellent diagnostic features. Microfilariae were well stained by