

reason that suprarenal fat (to include brown fat) was included among the tissues from cases of sudden, unexplained death in infancy which we had virologically tested⁵: both enteroviruses and adenoviruses were isolated from these fat samples, but there were no parallel histological studies. It would have been interesting to have virological data in the cases reported by Stephenson and Variend, especially as the diagnoses of their cases 2, 4, and 8 could well have resulted from virus infections. A combined virological and histological investigation might be worth while.

NR GRIST*

GED URQUHART

*Communicable Diseases (Scotland) Unit,
Ruchill Hospital, Glasgow, G20 9NB.
Microbiology Department, Ninewells
Hospital, Dundee, DD1 9SY.

virological and histological investigation of the brown fat. A great number of cases, however, would need to be studied before a reasonable conclusion could be drawn in view of the apparent low incidence of brown fat necrosis. Immunostaining for virus in the tissue sections of the affected cases would seem a better prospect. We do not know, however, whether appropriate antibody for the viruses in question is available, nor indeed whether it could be applied to paraffin sections. If Grist and Urquhart are in a position to assist us in this regard we should be extremely grateful.

Giant cell myocarditis associated with lymphoma

In their immunocytochemical study of giant cell myocarditis associated with lymphoma¹ Hales, Theaker, and Gatter made the interesting observation that necrotic cardiac myocytes did not express desmin reactivity. In a recent study of skeletal muscle necrosis and regeneration in the rat² we observed a similar loss of desmin expression 24 hours after injection of the local anaesthetic bupivacaine (fig 1). Loss of staining for desmin (using the antibody DE-R-11 from Dakopatts) occurred in fibres which were morphologically normal but which, from evidence in muscles sampled at later dates, were destined to undergo necrosis and

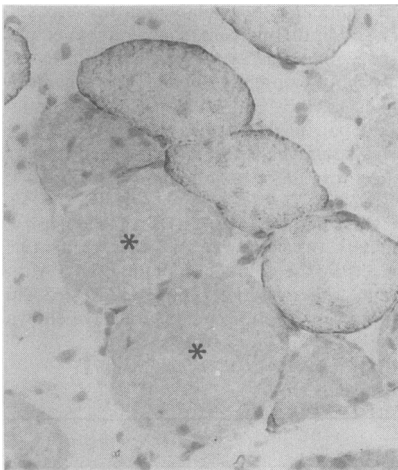


Fig 1 Rat tibialis anterior muscle 24 hours after bupivacaine injection. Damaged fibres (*) show loss of desmin expression while adjacent normal fibres show peripheral ring of staining for desmin. (Immunoperoxidase.)

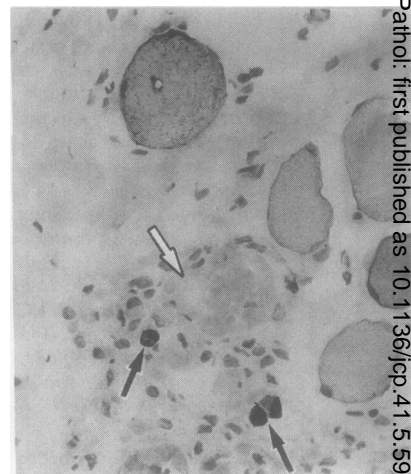


Fig 2 Human tibialis anterior muscle from a 6 year old with Duchenne dystrophy. A necrotic fibre is unstained (arrowhead) while small regenerating fibres are strongly stained for desmin (arrow). (Immunoperoxidase.)

phagocytosis. Desmin expression is also absent in necrotic fibres in human myopathies³ (fig 2). It would seem that desmin expression, at least as shown by the antibody DE-R-11, is lost at an early stage of skeletal muscle fibre degeneration. The immunohistochemical detection of this loss of expression may provide a sensitive indicator of muscle damage in diagnostic specimens

TR HELLIWELL

RHT EDWARDS

Departments of *Pathology and Medicine
University of Liverpool
Royal Liverpool Hospital
PO Box 147
L69 3BE

References

- 1 Hales SA, Theaker JM, Gatter KC. Giant cell myocarditis associated with lymphoma: immunocytochemical study. *J Clin Pathol* 1987;40:1310-3.
- 2 Helliwell TR. Lectin binding and desmin staining during bupivacaine-induced necrosis and regeneration in rat skeletal muscle. *J Pathol* 1988;154:99.
- 3 Thornell L-E, Eriksson A, Edstrom L. Intermediate filaments in human myopathies. *Cell and Muscle Motility* 1983;4:85-136

Dr Theaker comments:
I have investigated this further and have confirmed that desmin expression is lost from cells showing myocytolysis in other

References

- 1 Stephenson TJ, Variend S. Visceral brown fat necrosis in postperinatal mortality. *J Clin Pathol* 1987;40:896-900.
- 2 Afzelius BA. *Brown adipose tissue in infections*. New York: American Elsevier, 1970.
- 3 Roberts GBS, Boyd JF. The histopathology of enterovirus infections of new-born mice. *J Infect* 1987;15:45-56.
- 4 Grist NR, Roberts GBS, Cossackie A7 infections of rodents. *Arch ges Virusforsch* 1966;19:454-63.
- 5 Urquhart GED, Grist NR. Virological studies of sudden unexplained infant deaths in Glasgow 1967-70. *J Clin Pathol* 1972;25:443-6.

Dr Stephenson and Variend comment:

We thank Grist and Urquhart for their interesting comments. We were unaware of the reports relating to an affinity between virus and brown adipose tissue. This was despite a careful search of published data carried out before our study.

Virological studies are carried out routinely in our cases but these are limited to immunofluorescence of lung tissue for respiratory syncytial virus, parainfluenza I and II; additionally, a stool specimen is examined electron microscopically and by culture. In the miscellaneous group showing brown fat necrosis rotavirus was found in the stool in case 6 and histological assessment in cases 2 and 8 did suggest viral infection of some of the tissues. Two cases of unexplained death with brown fat necrosis showed cytomegalovirus inclusions limited to the parotid gland.

Grist and Urquhart suggest a combined