

that the three grade system should be abandoned in favour of a simplified version.⁴ For the working party to ignore this objective evidence and to propose complicating further the CIN system with an additional "borderline" group we regard as astonishing! The diagnosis of CIN I in the presence or absence of viral changes or inflammation was correctly made by both the Scottish and the Welsh groups only slightly more often than would have occurred by chance. Therefore, the addition of an extra low grade category "basal abnormalities of uncertain significance"¹ can only increase this confusion. The present working party has not suggested any new diagnostic criteria nor has it suggested any additional techniques which might be used to clarify this diagnostic difficulty. At the moment there is no way in which to determine the "correct" answer in any individual case. We would be very interested to know whether the members of this expert group are carrying out an objective study, similar to the ones done previously, of the "robustness" of their new classification.

J SWANSON BECK
SR HOWATSON
FD LEE
AM LESSELLS
KM MCLAREN
JG SIMPSON
GD SMITH
HB TAVADIA
F WALKER

University Department of Pathology,
The Western Infirmary,
Glasgow, G11 6NT

- 1 Anderson MC, Brown CL, Buckley CH, *et al.* Current views on cervical intraepithelial neoplasia. *J Clin Pathol* 1991;44:969-78.
- 2 Robertson AJ, Anderson JM, Swanson Beck J, *et al.* Observer variability in histopathological reporting of cervical biopsy specimens. *J Clin Pathol* 1989;42:231-8.
- 3 Ismail SM, Colclough AB, Dinnen JS, *et al.* Observer variation in histopathological diagnosis and grading of cervical intraepithelial neoplasia. *Br Med J* 1989;298:707-10.
- 4 Richart RM. A modified terminology for cervical intraepithelial neoplasia. *Obstet Gynecol* 1990;75:131-3.

BOOK REVIEWS

Glomerular Pathology. W Lawler. (Pp 208; £60.) Churchill Livingstone. 1991. ISBN 0-443-04062-1.

This monograph consists of a series of short chapters with concise text and numerous illustrations covering the various types of glomerular changes encountered in renal biopsy material. Instead of detailed references there are lists of additional reading material at the end of each chapter. In the preface we are told that this book is aimed at the junior histopathologist and, certainly, the text would seem appropriate at this level of experience and training. My only real quarrel with the text is that in chapter 11 the author fails to explain the difference between those types of focal proliferative glomerulonephritis which have developed on a background of diffuse mesangial disease as in IgA disease, lupus, etc.) and those which have not (microscopic polyarteritis and Wegener's etc).

In the individual chapters the author places the "clinical features" section at the end

which I consider inappropriate because the whole approach to diagnosis should be based on the clinical setting in which the renal biopsy specimen has been obtained. My particular concern is that the clinical data should not be regarded as unimportant which is the most likely conclusion if it is placed at the end of a chapter. So often nephrologists do not appreciate how valuable clinical data can be to the renal pathologist faced with a difficult biopsy specimen.

The final point about this book is that the illustrations of light microscopy are generally poor with a rather "foggy" appearance. They lack the sharpness, which is essential for demonstrating the finer aspects of glomerular changes. In some cases the staining technique appears less than ideal but, regardless of this problem, the photographic technique appears to be quite poor. In contrast the electron micrographs are of good quality.

DR TURNER

Cytokines. MJ Clemens. **The Medical Perspectives Series.** (Pp 122; paperback. £11.95.) BIOS Scientific Publishers. 1991. ISBN 1-872-74870-8.

This book offers a straightforward introduction to cytokines, covering a wide range of topics such as cytokine structure and function, signal transduction, oncogenes, cytokine gene expression, the biological roles of cytokines in both health and disease, finishing with a chapter on cytokines as potential therapeutic agents.

The chapter on signal transduction is especially good, providing a simplified yet detailed description of a complicated subject, as is the coverage of oncogenes. Throughout the whole book the authors include tables of basic yet useful scientific properties such as molecular weights, exon numbers, chromosome location of genes, affinity constants as well as biological data such as cytokine networks, and principle producing cells under a wide variety of stimuli. This combination of basics with detail makes this an excellent book for researchers and students new to the cytokine field, as well as established researchers who may need specific details or who would like to broaden their knowledge, to related areas. On the negative side we feel that the authors overuse the Interferons in examples, and could have sometimes used the Interleukins as an alternative.

Overall, this volume is excellent and successfully approaches an extremely diverse and complicated field in a straightforward manner.

CA MCINTYRE
RC REES

Biopsy Pathology of Muscle. 2nd ed. M Swash, MS Schwartz. **Biopsy Pathology Series 15.** (Pp 237; £50.) 1991. ISBN 0-412-34880-2.

This is the second edition of this volume on muscle biopsy pathology. As with other books in the series this is a bench book, intended for the use of the diagnostic histopathologist who receives muscle biopsy specimens, and for trainees in neuropathology and histopathology.

The book has 11 chapters, and starts with the structure of normal muscle and the indications for performing a muscle biopsy.

A methods and techniques section follows in which the biopsy procedure is described with a detailed account of the treatment of the specimen in the laboratory. The characteristics of normal muscle, including morphometric features, are followed by the histological appearances of disordered muscle under the headings: inflammatory myopathies; muscular dystrophies; "benign" myopathies of childhood; metabolic, endocrine and drug induced myopathies; and neurogenic disorders. For the sake of completion there is a chapter on tumours. The book is well illustrated throughout with light and electron micrographs.

The publication is timely as there are few books to guide the practising histopathologist in the interpretation of muscle biopsy specimens. It is up-to-date and practical, and is likely to serve most of the needs of the readership for whom it is intended.

M HONAVAR

Thymus Update. 4 The Thymus in Immunotoxicology. Ed MD Kendall, MA Ritter. (Pp 360; no price given.) Harwood Academic Publishers. 1991. ISBN 3-7186-5113-0.

This book is fourth in a series on aspects of the thymus which has previously covered the thymic microenvironment, T lymphocyte differentiation, and its role in tolerance induction. All very sound and predictable, but this next volume sounds rather unpromising. Do not be put off by the title, however, immunotoxicology appears to include not just dioxins and organo-tin compounds, but acyclovir, cyclosporin, and FK506, even trauma and stress. We all know the effects of thymectomy, and how the thymus changes in size with disease and involutes with age. Most of us have heard of thymic education, apoptosis, and the programmed death of lymphocytes. Fewer are familiar with concepts of autoimmunity arising from the effects of thymus damage. And it is only the international cabal of thymus researchers who grapple with the finer detail of the effects of drugs on the cells and ultrastructure of the thymic microenvironment. Fascinating but esoteric stuff.

The preoccupations of this international community then fill what is essentially an upmarket hardback newsletter—what the crucial citations are, which PhD theses are worth reading, where to submit your thymus-related manuscripts, which were the good conferences and where they will meet next. More and more of us need thymic education, and the insight this book gives into the state of the art make it a useful library buy—but the other volumes will be needed too.

RS PEREIRA

Biopsy Interpretation of Lymph Nodes. Biopsy Interpretation Series. SH Swerdlow. (Pp 412; £110.00.) Raven Press. 1992. ISBN 0-88167-840-6.

This is the first book on the interpretation of lymph node biopsy specimens to give full recognition to the role of modern techniques, including immunohistochemistry and molecular biology, in making the correct diagnosis. The book is set out more or less in the traditional manner except that it begins with a

Lesley Fallowfield serves as a timely reminder which should be essential reading for clinicians. Algorithms are discussed, but we would question their usefulness. The way to learn to diagnose malignant melanomas is to see them and to be taught about them in a clinical setting.

E HIGGINS
A DU VIVIER

Systemic Pathology. 3rd ed. Vol 7. **Thymus, Lymph Nodes, Spleen and Lymphatics.** Ed K Henry, W St C Symmers. (Pp 1042; £140.) Churchill Livingstone. 1992. ISBN 0-443-03429-X

The new Symmers volume on haematopathology is a brave attempt to encompass all you need to know about the subject in a little short of 1000 pages. The stage is set with a short introductory essay on basic immunology and this is followed by what is essentially a comprehensive textbook on the thymus. Three chapters are devoted to the normal lymph node and non-neoplastic lymphadenopathies and are followed by a chapter on the spleen which, curiously, hardly addresses lymphoma. The following chapter of some 350 pages, while entitled "neoplastic disorders of lymphoreticular tissue," deals essentially with lymph node neoplasms with only the occasional mention of extranodal lymphomas. A section on immunohistochemistry rounds off the haematopathology, but is followed by a quite irrelevant chapter on lymphatics which surely belongs elsewhere.

There is much to be commended in this book. With few exceptions, including the extranodal lymphomas referred to above, its coverage is encyclopaedic, it is comprehensively illustrated, and the index is unusually good. It is appropriately easy to use and, consequently, will be a useful bench book. The chapter on the thymus is especially valuable because there is no other comparable text on this subject. It is a pity, however, that the Müller-Hermelink classification of thymomas, although praised, is not used.

However, this book cannot be recommended to those seeking enlightenment about this difficult and sometimes controversial branch of pathology. The two short chapters at the beginning and end of the book, on basic immunology and immunohistochemistry, respectively, comprise the only gestures to "science". Molecular genetics, which has contributed so much to recent advances in our understanding of haematopathology, does not feature at all. It is, surely, inexcusable not to have mentioned immunoglobulin light chain restriction, CD10 positivity, immunoglobulin gene rearrangement and the t(14;18) translocation in the 25 pages and 42 illustrations devoted to follicular lymphoma. Pathologists are now much less exercised about the classification of non-Hodgkin's lymphomas than this book would suggest, having settled for either the working formulation or the updated Kiel classification. Developments in immunophenotyping and molecular genetics are beginning to stimulate new thoughts about lymphoma classification, but in this respect the book moves decisively backwards to the largely abandoned classification of the British National Lymphoma Investigation.

The publishers of this series have, for some reason, chosen to persist with the same dull

format as that of the first (1966) edition. The illustrations are also rather flat and grey. The aim seems to be to present British pathology as a dignified, conservative descriptive discipline; this accentuates the faults of this book and masks its strengths. The authors deserve better.

P G ISAACSON

Biopsy Pathology of the Skin. N Kirkham. **Biopsy Pathology Series 16.** (Pp 396; £59.50.) Chapman & Hall. 1991. ISBN 0 412 35080 7

I must admit to being a little sceptical when this compact volume of just under 400 pages arrived on my desk. This scepticism arose from my doubt that a book purporting to cover biopsy pathology of the skin could be easily carried in my overcoat pocket.

I had a pleasant surprise. Not only did I find this book easy to read (probably due to Dr Kirkham's rather anecdotal and idiosyncratic style) but also when put to the acid test of lying next to my microscope for a few weeks I found myself referring to it rather more often than some of the larger texts on my shelf. Obviously a book of this size cannot and does not claim to be comprehensive. I think that the balance of the various sections is about right and some of the more contentious areas of dermatopathology, such as the melanocytic lesions, are given ample consideration. Any shortfalls in the included material are to some extent compensated by the remarkably up to date references. The photomicrographs, both colour and black and white, are good and the index appears to work pretty well. All in all this book is good value and is yet another worthwhile addition to this series.

S HUMPHREYS

NOTICES

ACP Locum Bureau

The Association of Clinical Pathologists runs a locum bureau for consultant pathologists.

Applicants with the MRCPATH who would like to do locums and anyone requiring a locum should contact The General Secretary, 221 Preston Road, Brighton BN1 6SA. Tel (0273) 561188. Fax: (0273) 541227.

Melanoma '93

A joint meeting of the Royal College of Pathologists and the Melanoma Study Group, sponsored by the South East Thames Regional Health Authority Quality Initiative.

6 and 7 May 1993,
Brighton Conference Centre

This two day consensus conference will address problems in the biopsy diagnosis of melanocytic disorders. As well as formal presentations by Bernard Ackerman (New York) and David Elder (Philadelphia), the programme will include presentations and discussions of proffered cases and papers. Hotel accommodation and car parking will be available at discount rates. The conference takes place during the Brighton International Festival. A spouse programme will be available.

Further details are available from Dr N Kirkham, Dept. of Histopathology, Royal Sussex County Hospital, Brighton BN2 5BE, UK. Fax: 0273-600182.

Corrections

An author's name was accidentally omitted from the list on a piece of correspondence: Current views on cervical neoplasia (*J Clin Pathol* 1992;45:643). We apologise to Dr R A Burnett.

In the same issue the legend of the following figure was incomplete (Misbah *et al*, *J Clin Pathol* 1992;45:624-7). The correct version is reproduced below:

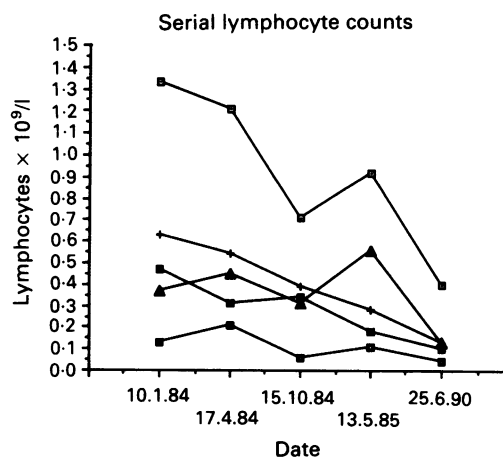


Figure 1 Serial lymphocyte counts. Normal ranges: —□— total lymphocytes (2.0-4.0) × 10⁹/l, —+— CD3 (0.6-1.5), —■— CD4 (0.4-1.0), —■— CD8 (0.2-0.7), —▲— B cells (0.1-0.5).