

Correspondence

Safer staining method for acid fast bacilli

I read with interest the article by Ellis and Zabrowarny on the use of a non-phenolic staining solution for acid fast bacilli and can report that the technique works well in our hands.¹ Any modification of standard staining techniques that can reduce the use of hazardous chemicals is to be welcomed and to that end we substituted phenol with the LOC High Suds in several other methods used in this department.

The following techniques were tried:

- Long Ziehl-Neelsen stain, for lipofuchsin²;
- Lendrum's carbol chromatrope, for eosinophil granules³;
- Gram's stain (where dilute carbol fuchsin is used to stain Gram negative organisms) for bacteria⁴;
- Modified Ziehl-Neelsen stain, for cryptosporidia.⁵

I can report, in each case, that the results obtained were comparable with those obtained with the original techniques. I would recommend the use of LOC High Suds in all of these techniques as a safer, cheaper substitute for phenol.

B KELLY

Department of Veterinary Pathology,
Royal (Dick) School of Veterinary Studies,
The University of Edinburgh, Summerhall,
Edinburgh EH9 1QH

- Ellis RC, Zabrowarny LA. Safer staining method for acid fast bacilli. *J Clin Pathol* 1993;46:559-60.
- Pearse AGE. *Histochemistry—theoretical and applied*. 1st Edn. Edinburgh: Churchill Livingstone, 1950.
- Lendrum AC. The staining of eosinophil polymorphs and enterochromaffin cells in histological sections. *J Pathol Bacteriol* 1944;56:3.
- Granger Davies. *Veterinary pathology and bacteriology*. 4th Edn. London: Bailliere, Tindall and Cox, 1960.
- Henriksen P. Staining of cryptosporidia by a modified Ziehl-Neelsen technique. *Acta Vet Scand* 1981;22:594-6.

Dr Ellis comments:

We also have had excellent results with the long Ziehl-Neelsen stain for lipofuchsin, but have not tried to substitute LOC High Suds in the other methods mentioned mainly because they are not methods we commonly use.¹ Our primary aim is to investigate and develop safer methodology for those techniques used in this department.

The method currently under development is a modification of Fite and Faraco's method for *Mycobacterium leprae*.² We have developed a staining solution to replace carbol fuchsin which contains LOC High Suds, with which we have had considerable success. I hope that the method will be published after further trials in other laboratories and after staining a wider range of tissues.

- Pearse AGE. *Histochemistry—theoretical and applied*. 1st Edn. Edinburgh: Churchill Livingstone, 1950.
- Fite GL, Cambre FJ, Turner MH. Procedures for demonstrating lepra bacilli in paraffin sections. *Arch Pathol* 1947;43:624-5.

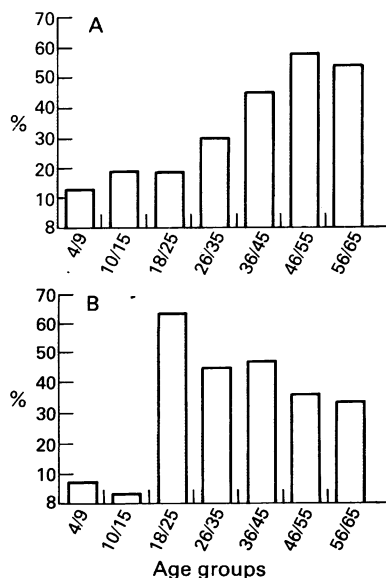
Seroconversion for *Helicobacter pylori*

Kuipers *et al*¹ recently reported a very low seroconversion for *Helicobacter pylori* infection in an adult population. They measured *H pylori* immunoglobulin G (IgG) antibodies in two serum samples taken from each of 115 patients, obtained with a mean interval of 11.5 years, and found that only two patients became infected during follow up. From their data, the authors suggested that the age related increase in *H pylori* prevalence was due to a dominant infection rate in childhood. Data on seroconversion in an untreated population are quite scarce. We report our data on 207 asymptomatic Italian children (aged 4-15 years) and 1010 blood donors (aged 18-65 years) who have been assessed serologically for both IgG and IgM (by in-house enzyme linked immunosorbent assay (ELISA), with a specificity and sensitivity of 93%).²

Our results show that the prevalence of *H pylori* IgG antibodies increases with age, both in children and in adult blood donors, but that the prevalence of *H pylori* IgM antibodies is highest in the 18-25 year age group and that it decreases with age (figure). Concentrations of IgG or IgM antibodies in *H pylori* positive patients (measured by optical density at 470 nm) did not change with age. Our data strongly support their hypothesis of an age-cohort effect, with the acquisition of most *H pylori* infection during youth (below the age of 20 years).

High IgM titres consistent with a first contact with the infection associated with low IgG titres, that consistently correlate with active *H pylori* gastritis, may support the hypothesis of a spontaneous elimination

High concentrations of IgG antibodies to *H pylori* in 1010 blood donors and 207 healthy children



Prevalence of high serum IgG (I) and IgM (II) antibodies to *H pylori* according to age in 1217 Italians: a first contact with the infection mostly occurs in youth, but most of the younger subjects will spontaneously eliminate it.

of the infection in young patients.³ A spontaneous elimination of the first infection was shown in 33 out of 134 Gambian children aged 1-15 months by measuring serum antibodies and performing a ¹³C urea breath test every month over a period of 2 years.⁴ Most contact with *H pylori* infection occurs in childhood, but the majority of younger subjects will spontaneously eliminate it. In Italians this occurs mostly during the second or third decade and in Gambians in the first 5 years of life; the difference is probably related to either hygiene conditions or the nutritional status of the population.

G ODERDA

Paediatric Gastroenterology,
University of Turin,
Piazza Polona 94,
10126 Torino, Italy

D VAIRA

1st Medical Clinic,
University of Bologna,
Bologna, Italy

J HOLTON

Department of Microbiology,
University College and Middlesex
School of Medicine, London

- Kuipers EJ, Pena AS, van Kamp G, *et al*. Seroconversion for *Helicobacter pylori*. *Lancet* 1993;342:328-31.
- Oderda G, Vaira D, Holton J, *et al*. Serum Pepsinogen I and IgG antibody to *Campylobacter pylori* in non-specific abdominal pain in childhood. *Gut* 1989; 30:912-16.
- Mitchell JD, Mitchell HM, Tobias V. Acute *Helicobacter pylori* infection in an infant, associated with gastric ulceration and serological evidence of intra-familial transmission. *Am J Gastroenterol* 1992;87:382-6.
- Thomas JE, Downes RB, Lunn PG, *et al*. Seroepidemiology of *Helicobacter pylori* infection in early childhood. *Gut* 1992;32: A1231-2.

Tissue artefacts caused by sponges

Following the recent correspondence by Platt and Newman regarding the use of tea-bags or synthetic Shandon bags in the processing of small biopsy specimens, we wish to draw attention to a tissue artefact which may occur when such specimens are processed in synthetic bags.¹

Following the discovery that triangular shaped defects in renal and liver biopsy specimens were due to the use of foam sponges in embedding cassettes,² we changed our procedure and processed all such specimens wrapped in perm paper. Recently, however, our laboratory ran out of perm paper and for a few weeks we processed renal biopsy specimens in Shandon bags. We soon noticed that a regular elliptical defect (fig 1) was occurring in tissue sections. Close inspection of the bag

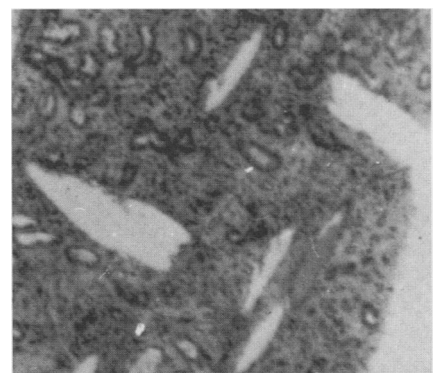


Figure 1 Elliptical effect in tissue sections.