

Oesophageal histology in long term users of non-steroidal anti-inflammatory drugs

A S Taha, S Dahill, I Nakshabendi, F D Lee, R D Sturrock, R I Russell

Abstract

Aims—To study the oesophageal histological changes in long term users of non-steroidal anti-inflammatory drugs (NSAIDs) compared with patients not receiving these drugs.

Methods—Ninety eight patients were studied, 53 of whom had taken NSAIDs for three years; 45 had not. Oesophageal biopsy specimens were taken from healthy-looking mucosa in the lower third of oesophagus. The papillary length, the thickness of the basal cell layer, and the intensity of cells infiltrating the epithelium were all assessed blind.

Results—The NSAID group included four (7%) cases of papillary elongation and two (4%) cases of basal cell hyperplasia, compared with 13 (29%; $p < 0.01$) and eight (18%; $p < 0.02$), respectively, in patients not taking NSAIDs. The total histological scores were also lower in patients treated with NSAIDs.

Conclusion—Long term NSAID users have fewer oesophageal histological abnormalities than patients not receiving NSAIDs. Macroscopic damage related to NSAID use is, therefore, unlikely to require pre-existing histological oesophagitis for its development.

(J Clin Pathol 1994;47:705-708)

Mucosal inflammation has always been the focus of attention of both clinicians and pathologists alike because of its association with subsequent complications such as ulceration. Indeed, inflammation and ulceration are increasingly being accepted as two points in a disease spectrum with a common pathogenetic mechanism. There are several examples to support this, including inflammatory bowel disease, chronic gastritis, and duodenitis.^{1,2}

Non-steroidal anti-inflammatory drugs (NSAIDs) remain among the most widely used group of drugs worldwide, and their side-effects could involve any part of the gastrointestinal tract.^{3,4} Histopathological changes related to NSAIDs in the stomach,⁵ duodenum,⁶ and the small and large intestine⁷ have been well documented, but very little is known about their effect on the oesophagus. This paper aims to rectify that by comparing a group of long term NSAID users with a group not taking these drugs.

Methods

Patients, aged 18 years or over, were recruited from the rheumatology and gastroenterology outpatient clinics. NSAIDs had to have been taken for at least four weeks before endoscopy. Patients not taking NSAIDs had to have an indication for endoscopy, such as upper abdominal complaints, because of ethical considerations. This was not the case in patients taking NSAIDs because of the known risk of asymptomatic damage in such a group.⁸ Patients were excluded if they had taken anti-ulcer drugs or vasodilators within four weeks of endoscopy, because of the effect of the former on acid secretion, and the potential of the latter to increase gastro-oesophageal reflux. Patients were also excluded if they had local oesophageal or systemic malignancy, a history of Crohn's disease, or previous upper gastrointestinal surgery, because of the effect of these factors on oesophageal histology.

Informed consent was obtained and patients were endoscoped after an overnight fast. Diazepam or midazolam, 3-10 mg, were given intravenously for sedation.

In a preliminary assessment we found that the histological features of erosive or ulcerative oesophageal lesions in NSAID users were identical with those of non-users, although the neighbouring mucosa was less likely to look histologically inflamed in NSAID users. In the current study an average of two biopsy specimens were therefore taken from healthy-looking mucosa in the lower third of oesophagus, about 5 cm proximal to the cardia, and fixed in a standard solution of formol-saline. This is the area most likely to be affected by gastro-oesophageal reflux and by NSAID-related endoscopic damage.⁹ Two gastric antral biopsy specimens were also taken to test for *Helicobacter pylori* by culture and histology.

The oesophageal histological findings (figs 1 and 2) were graded on a four point scale: 0, no lesion or normal; 1, very mild or possible; 2, a definite mild or moderate lesion; and 3, a severe lesion. The following features were studied.

Papillary elongation: normal length was up to 60% of the distance between the basal layer and the luminal surface.

Basal cell hyperplasia: a single layer was considered to be normal, and a definite abnormality was represented by at least two layers.

Cells in the epithelium: grade 0 was equivalent to the total absence of eosinophils or polymorphs; grade 1, less than five cells in the whole biopsy specimen; and grade 3, more

Department of Gastroenterology

A S Taha
I Nakshabendi
R I Russell

Department of Pathology

S Dahill
F D Lee

Department of Rheumatology, Royal Infirmary, Glasgow G31 2ER, Scotland
R D Sturrock

Correspondence to:
Dr A S Taha,
Gastrointestinal Centre,
Southern General Hospital,
Glasgow G51 4TF, Scotland

Accepted for publication
11 January 1994

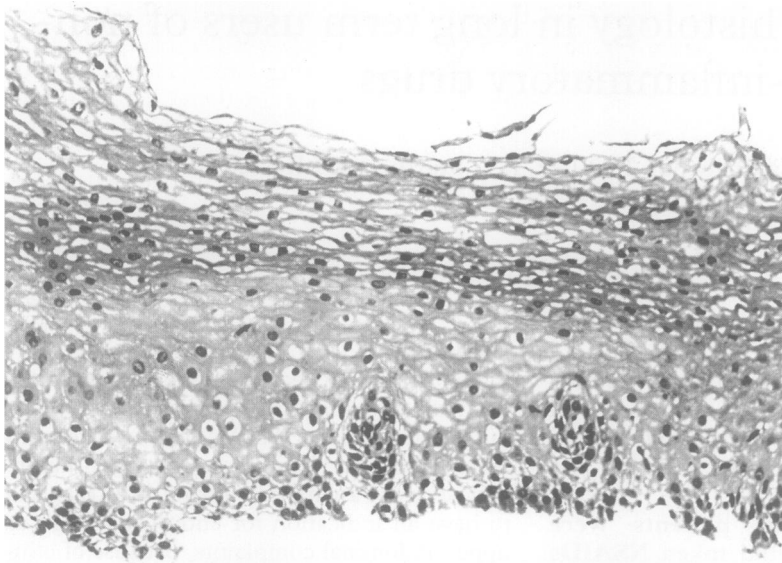


Figure 1 Normal oesophageal mucosa.

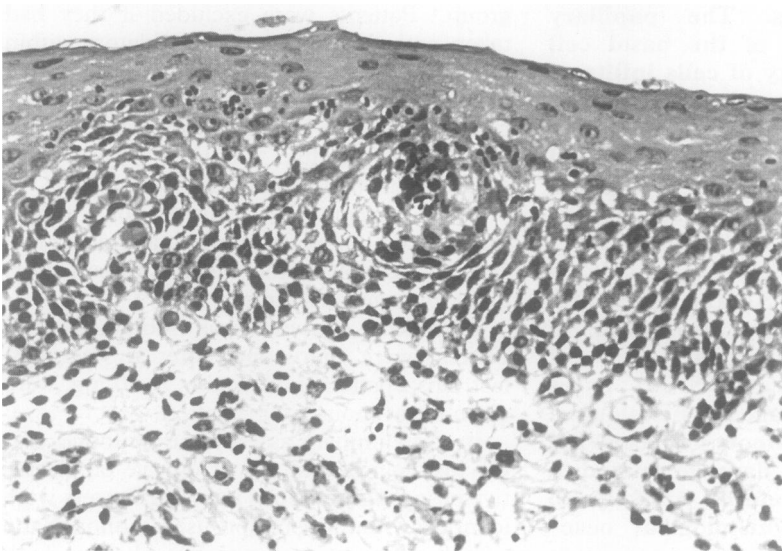


Figure 2 Some features of reflux oesophagitis: basal cell hyperplasia and inflammatory cell infiltration. The papillary size is at the upper limit of normal.

than five cells. The intraepithelial lymphocytes were also graded as above and the score added to that of other cells, which in some cases might give a score greater than 3 for the infiltrative cell count. In the assessment of papillary elongation, basal cell hyperplasia, and the inflammatory cell counts, biopsy specimens scoring 1 or less were considered to be within normal limits. In the overall global score (comprising the sums of all the above

Table 1 Patients' characteristics and demographic details

	Receiving NSAIDs (n = 53)	No NSAIDs (n = 45)
Men	13	19
Women	40	26
Age (years), median (interquartile ranges)	58 (49–65)	52 (45–63)
Smokers	26	31
Drinkers	16	18
Abdominal complaints	29	45
Oesophageal erythema	4	3
Gastric ulcers	8	2
Duodenal ulcers	5	10
Gastric <i>H pylori</i>	31	36

Table 2 Types of NSAID used

Agent	n
Indomethacin	10
Naproxen	8
Diclofenac	6
Ketoprofen	5
Piroxicam	4
Others*	20
Total	53

* Two to three patients per one of the following: azapropazone, etodolac, fenbufen, flurbiprofen, ibuprofen, nabumetone, sulindac, and tenoxicam.

assessments) specimens scoring 4 or less were considered normal.

Statistical analyses included the χ^2 test and Fisher's exact test, where appropriate. All biopsy specimens carried code numbers, and all assessments were conducted blind.

Results

Ninety eight patients were studied, 53 of whom were taking NSAIDs. Their clinical characteristics are shown in table 1. There were no significant differences in the age distribution, male:female ratio, smoking or drinking habits between the two groups. However, there were fewer patients with abdominal complaints in the NSAID group. This is because of the inclusion criteria that permitted entry into the study of asymptomatic NSAID users. Despite this difference, both groups had comparable numbers of peptic lesions, which were more likely to be found in the stomach of patients taking NSAIDs.

The types of NSAIDs used are shown in table 2. Most agents are known for their potent antiarthritic and ulcerogenic potentials. They were all taken in therapeutic doses for a median duration of three years.

Figure 3 gives the overall oesophageal histological scores as well as those of the three major histological features: papillary elongation; basal cell hyperplasia; and the infiltrative cell count. The differences between the two groups became more obvious when a line was drawn to separate the abnormal from the normal scores. Patients not taking NSAIDs included more cases with abnormal scores, especially with respect to papillary elongation

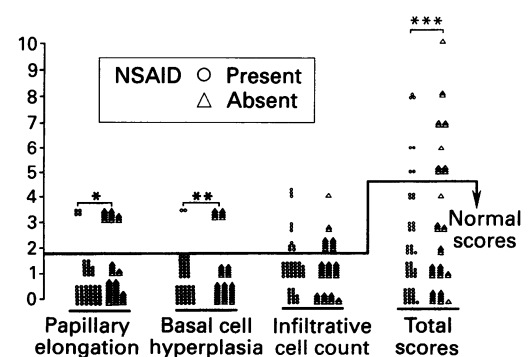


Figure 3 The oesophageal histological scores in the presence or absence of NSAIDs. The NSAID group have fewer abnormal cases especially with respect to papillary elongation, basal cell hyperplasia, and the total scores. Significant rise compared with NSAID patients: * $p < 0.01$; ** $p < 0.02$; *** $p < 0.05$.

and basal cell hyperplasia. The abnormal scores tended to be more severe in the absence of NSAIDs as shown in the total scores scattergram.

It is also worth noting that a sizeable number of subjects with papillary elongation, regardless of NSAID intake, were smokers (16/17;94%), associated with gastric *H pylori* infection (15/17; 88%), and had a total of seven duodenal ulcers (7/17;41%). Also, of 10 patients with basal cell hyperplasia, in the presence or absence of NSAID use, seven (70%) were smokers, seven (70%) had gastric *H pylori* infection, but no duodenal ulcers were found in this group.

Discussion

This study shows that long term NSAID intake is associated with fewer oesophageal histological abnormalities, especially those related to papillary elongation and basal cell hyperplasia. The latter two abnormalities are also associated with smoking and with the presence of gastric *H pylori*, regardless of NSAID intake.

The explanation for the above findings may be facilitated by considering the mechanisms that are known to influence the function and integrity of the oesophageal mucosa, and their possible interaction with NSAIDs. These consist mainly of factors that contribute to gastro-oesophageal reflux, including malfunction of the lower oesophageal sphincter, excess gastric contents (especially acid), poor gastric emptying, smoking and drugs, as well as other intrinsic oesophageal factors such as narrowing and poor motility.^{10 11} They all have in common prolonged exposure of the mucosa to the various injurious agents.

Acute exposure to NSAIDs is known to stimulate gastric acid secretion,^{12 13} and three years into this study it is not clear whether this applies to long term NSAID intake.

Another factor that needs to be considered is the interaction between NSAIDs and prostaglandin E₂ (PGE₂). Oesophagitis is associated with a local increase in the activity of PGE₂.¹⁴ Although such an increase could simply be due to inflammation itself, some workers believe that PGE₂ has a pro-inflammatory effect in the oesophagus.¹⁵ Acetylcholine, known to increase the lower oesophageal sphincter pressure,¹⁶ is suppressed by PGE₂¹⁷ which, as a result, relaxes the lower oesophageal sphincter and might encourage gastro-oesophageal reflux. The inhibition of PGE₂ by NSAIDs could, at least in theory, decrease gastro-oesophageal reflux with its histological consequences. Papillary elongation and basal cell hyperplasia are known features of gastro-oesophageal reflux.¹⁸ Their low prevalence in our NSAID group could be due to the reduction of gastro-oesophageal reflux, or the absence of the hypertrophic activity of PGE₂ already inhibited by NSAIDs.

Although the above mechanisms might explain the relative normality of the oesophageal histology in chronic NSAID

users, this does not necessarily imply that NSAIDs are protective to the oesophagus, as suggested by earlier experimental data,¹⁵ because of the following. Firstly, an increasing number of studies show oesophageal endoscopic damage related to NSAIDs^{9 19 20} even in healthy volunteers with normal findings on pretreatment endoscopy.²¹ Secondly, NSAIDs are generally acidic molecules with a Pk between 4 and 5, being relatively lipid soluble at low pH. In the presence of gastro-oesophageal reflux, when the pH of the distal oesophagus is less than 4, these drugs may enter the oesophageal mucosal cells, with direct toxic effects.¹⁹ Thirdly, the previous experimental models that showed indomethacin associated decreases in mucosal injury^{15 22} have recently been challenged by workers who eliminated the effect of extramucosal factors.²³ The latter have suggested that a PGE₂ analogue did not worsen clinical oesophagitis at low doses, and when higher antisecretory doses were used some improvement was noted in the degree of oesophagitis.²³

Our finding of an association between smoking and papillary elongation can be explained by the inhibitory effect of smoking on the lower oesophageal sphincter which in turn contributes to gastro-oesophageal reflux.²⁴ We cannot, however, explain the apparent association between oesophageal papillary elongation and gastric *H pylori*. To our knowledge, this has not been reported before, and the possibility of *H pylori* related interference with gastric motility,²⁵ which in turn might increase gastro-oesophageal reflux, cannot be excluded.

In conclusion, long term NSAID use is associated with a lower prevalence of histological abnormalities in the oesophagus. It is not, therefore, clear whether prior histological oesophagitis is essential for the development of NSAID related macroscopic damage in the oesophagus.

We thank Mrs Ruth Simpson for her secretarial assistance and Miss Pamela Boothman for her help with *H pylori* cultures.

- Dixon MF, Sobala GM. Gastritis and duodenitis: the histopathological spectrum. *Eur J Gastroenterol Hepatol* 1992;4(suppl 2):S17-23.
- Sipponen P. Long-term consequences of gastroduodenal inflammation. *Eur J Gastroenterol Hepatol* 1992;4(suppl 2):S25-9.
- Gibson T. Non-steroidal anti-inflammatory drugs—another look. *Br J Rheumatol* 1989;27:87-90.
- Barrier CH, Hirschowitz BI. Current controversies in rheumatology. Controversies in detection and management of non-steroidal anti-inflammatory drug induced side-effects on upper gastrointestinal tract. *Arthritis Rheum* 1989;32:926-9.
- Taha AS, Nakshabendi I, Lee FD, Sturrock RD, Russell RI. Chemical and Helicobacter pylori related gastritis in patients receiving non-steroidal anti-inflammatory drugs—comparison and correlation with peptic ulceration. *J Clin Pathol* 1992;45:135-9.
- Taha AS, Dahill S, Nakshabendi I, Lee FD, Sturrock RD, Russell RI. Duodenal histology, ulceration, and Helicobacter pylori in the presence or absence of non-steroidal anti-inflammatory drugs. *Gut* 1993;34:1162-6.
- Bjarnason I, Hayllar J, MacPherson J, Russell AS. Side effects of non-steroidal anti-inflammatory drugs on the small and large intestine in humans. *Gastroenterology* 1993;104:1832-47.
- Skander MP, Ryan FP. Non-steroidal anti-inflammatory drugs and pain-free peptic ulceration in the elderly. *Br Med J* 1988;297:833-4.
- Taha AS, Nakshabendi I, Sturrock RD, Russell RI. Non-steroidal anti-inflammatory drugs and the oesophagus—endoscopic and histological studies. *Gastroenterology* 1993;104:A203.

- 10 Janssens J, Vantrappen G. Pathophysiology of reflux oesophagitis. *Scand J Gastroenterol* 1989;156(suppl): 15-9.
- 11 Shay SS, Egli D, McDonald C, Johnson LF. Gastric emptying of solid food in patients with gastro-oesophageal reflux. *Gastroenterology* 1987;92:459-65.
- 12 Feldman M, Colturic TJ. Effect of indomethacin on gastric acid and bicarbonate secretion in humans. *Gastroenterology* 1984;87:1339-43.
- 13 Levine RA, Jyotirmoy N, King RL. Non-salicylate non-steroidal anti-inflammatory drugs augment pre-stimulated acid secretion in rabbit parietal cells. Investigations of the mechanisms of action. *Gastroenterology* 1991;101: 756-65.
- 14 Ottignon Y, Alber D, Moussard C. Oesophageal mucosal prostaglandin E₂ levels in health and gastrooesophageal reflux disease. *Prostaglandins Leuk Med* 1987;29:141-51.
- 15 Northway MG, Libshitz HI, Osborne BM. Radiation oesophagitis in the opossum; radioprotection with indomethacin. *Gastroenterology* 1980;78:881-92.
- 16 Rolling GT, Farrell RL, Castell DO. Cholinergic response of the lower oesophageal sphincter. *Am J Physiol* 1972;222:967-72.
- 17 Shore S, Collier B, Martin JG. Effect of endogenous prostaglandins on acetylcholine release from dog trachealis muscle. *J Appl Physiol* 1987;62:1837-44.
- 18 Collins BJ, Elliot H, Sloan JM, McFarland RJ, Love AHG. Oesophageal histology in reflux oesophagitis. *J Clin Pathol* 1985;38:1265-72.
- 19 Eng J, Sabanathan S. Drug-induced oesophagitis. *Am J Gastroenterol* 1991;86:1127-33.
- 20 Minocha A, Greenbaum DS. Pill-oesophagitis caused by non-steroidal anti-inflammatory drugs. *Am J Gastroenterol* 1991;86:1086-9.
- 21 Santucci L, Patocia L, Fiorucci S, Farroni F, Favero D, Morelli A. Oesophageal lesions during treatment with piroxicam. *BMJ* 1990;300:1018.
- 22 Eastwood GL, Beck BD, Castell DO, Brown FC, Fletcher JR. Beneficial effects of indomethacin on acid-induced oesophagitis in cats. *Dig Dis Sci* 1981;26:601-8.
- 23 Stein BE, Schwartzman ML, Carrol MA, Stahl RE, Rosenthal WS. Role of arachidonic acid metabolites in acid-pepsin injury to rabbit oesophagus. *Gastroenterol* 1989;97:278-83.
- 24 Dennish GW, Castell DO. Inhibitory effect of smoking on the lower oesophageal sphincter. *N Engl J Med* 1971; 284:1136-7.
- 25 McColl KEL. Helicobacter pylori colonization and alteration in gastric physiology. In: Rathbone BJ, Heatley RV, eds. *Helicobacter pylori and gastroduodenal disease*. 2nd edn. Oxford: Blackwell Scientific Publications, 1992:198-208.