

# Pancreatoblastoma: a histochemical and immunohistochemical analysis

Chen Hua, Xu Ke Shu, Chen Lei

## Abstract

**A case of pancreatoblastoma arising in a five year old girl was analysed using histochemical and immunohistochemical methods. The tumour was composed of tubular gland-like structures, squamoid components and some small round cells surrounding tubular structures. The cytoplasm of the small round cells and a few of the squamoid cells was positive on staining with Grimelius argyrophil stain. Immunohistochemically, tumour tissue was positive for neurone specific enolase. The cytoplasm of some of the small round cells was positive for insulin, glucagon, somatostatin, pancreatin polypeptide, thyroid stimulating hormone, follicle stimulating hormone, and neurotensin. These results suggest that this tumour arose from primitive multipotential stem cells, showing exocrine and neuroendocrine differentiation.**

(*J Clin Pathol* 1996;49:952-954)

**Keywords:** pancreatoblastoma, pancreatic neoplasm, immunohistochemistry, neuroendocrine cells.

Pancreatoblastoma or infantile carcinoma of the pancreas is a very rare primary pancreatic malignancy in infants and children. In 1971, Frable *et al*<sup>1</sup> reported a case of infantile carcinoma of the pancreas. Horie *et al*<sup>2</sup> in an attempt to account for the histological features of this tumour, suggested the term pancreatoblastoma. This tumour has been studied extensively using immunohistochemical techniques and electron microscopy.<sup>3</sup> Several authors have suggested that pancreatoblastomas contain islet cell components. Here, we report a case of pancreatoblastoma in a five year old girl and discuss the possible histogenesis of this unusual neoplasm.

## Case report

The patient, a five year old girl, was admitted to Qingdao Municipal Hospital in 1987 complaining of abdominal pain. The patient had had a poor appetite for the previous three months. She had diarrhoea and vomited three times during the three days prior to admission. Her past medical history was uninformative. On admission, her temperature was 36.5°C, respiratory rate was 28, pulse 112, and blood pressure 110/70. Physical examination revealed an 8 × 6 cm, fixed, firm and tender mass in the left upper abdomen. The edge of the liver was palpable 1.5 cm below the right costal

Table 1 Results of initial laboratory tests

Test	Value
Haemoglobin (g/l)	110
Blood urea nitrogen (g/l)	0.146
Aspartate aminotransferase (IU/l)	50
Amylase (IU/l)	194
Serum sodium (mmol/l)	146
Serum chloride (mmol/l)	96
Serum potassium (mmol/l)	3.74
CO <sub>2</sub> (mmol/l)	30.2
Glucose (g/l)	0.91
Alkaline phosphatase (IU/l)	125

margin. The spleen was not palpable. The patient's lymph nodes were not swollen.

Table 1 shows the results of the initial laboratory tests. Catecholamine qualitative analysis was negative. A B pattern ultrasonogram showed a 9.8 × 5.7 × 5.2 cm mass with lobules connected to the tail of the pancreas.

The mass and the surrounding pancreatic tissue were excised. The tumour had been located at the tail of the pancreas and had been connected to the transverse colon.

## Methods

Tumour tissue was fixed in 10% formalin and embedded in paraffin wax. Paraffin wax sections were stained with haematoxylin and eosin, periodic acid-Schiff (PAS) with and without prior digestion with diastase, Masson's trichrome, Grimelius argyrophil stain, and Masson-Fontana stain. Sections were stained immunohistochemically using the APAAP method. Rabbit antisera were used to detect expression of human chromogranin A, insulin, gastrin, glucagon, somatostatin, pancreatin polypeptide, adrenocorticotrophic hormone

Table 2 Antibodies used with dilutions and sources

Antibody	Dilution	Source
Chromogranin A	1 in 100	Dako
ACTH	1 in 25	Dako
Insulin	1 in 200	Dako
Glucagon	1 in 200	Dako
Somatostatin	1 in 200	Dako
Pancreatin polypeptide	1 in 100	Dako
Gastrin	1 in 300	Dako
Luteinising hormone	1 in 700	Dako
TSH	1 in 700	Dako
FSH	1 in 100	Dako
Neurotensin	1 in 100	Dr Chen Jia Jun
Serotonin	1 in 10	Dako
CEA	1 in 100	Dako
Cytokeratin	1 in 50	Dako
S100 protein	1 in 100	Dako
Neurofilament	1 in 50	Dako
NSE	1 in 100	Dako
Calcitonin	1 in 200	Dako
Anti-rabbit IgG	1 in 50	Dako
Anti-mouse IgG	1 in 50	Dako
Rabbit PAP	1 in 100	Dako
Mouse PAP	1 in 100	Dako

Source: Dako, Carpinteria, California, USA.

Department of  
Pathology, Qingdao  
Municipal Hospital  
Chen Hua  
Xu Ke Shu

Department of  
Physiology, Qingdao  
Medical College  
Chen Lei

Correspondence to:  
Dr Chen Hua, Department  
of Pathology, Qingdao  
Municipal Hospital,  
Qingdao, 266011, Shan  
Dong, China.

Accepted for publication  
5 September 1996

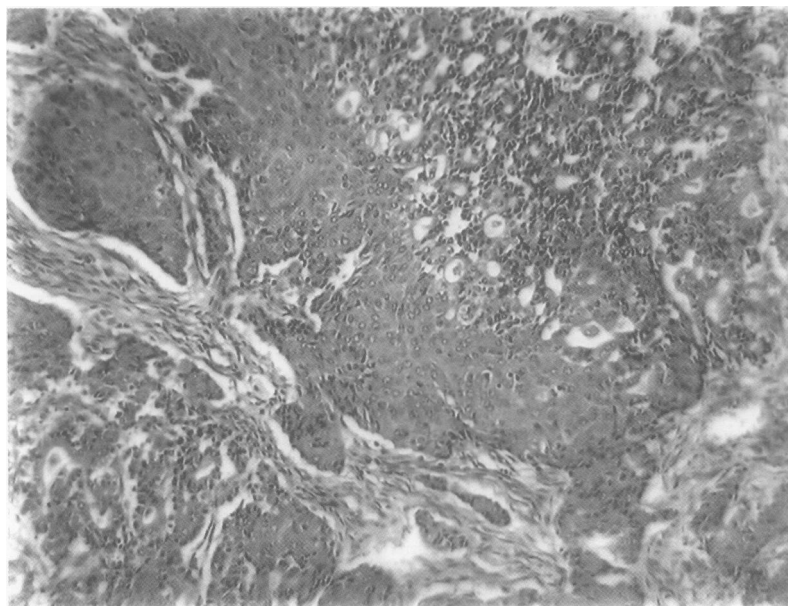


Figure 1 Section through the tumour showing tubular gland-like structures and squamoid components (haematoxylin and eosin; original magnification  $\times 120$ ).

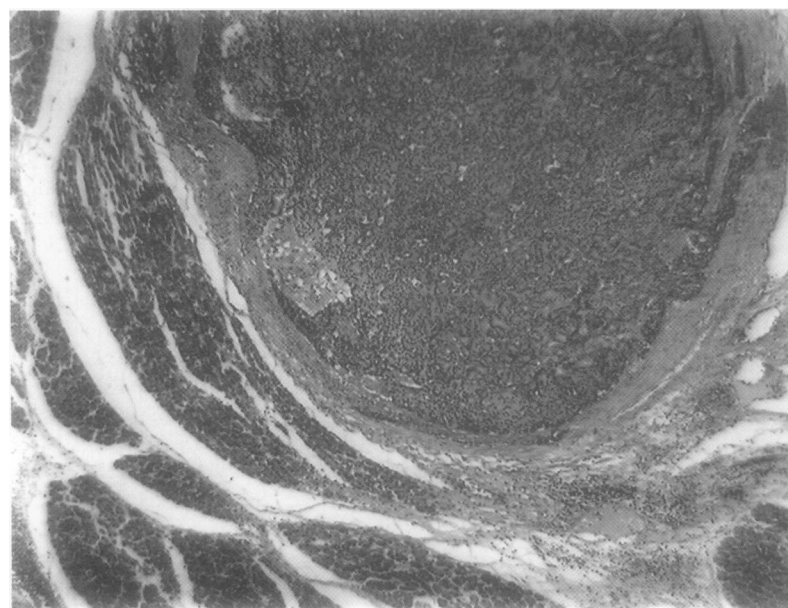


Figure 2 Tumour nodule formation with compression of surrounding pancreas (haematoxylin and eosin; original magnification  $\times 120$ ).

(ACTH), thyroid stimulating hormone (TSH), neurone specific enolase (NSE), follicle stimulating hormone (FSH), luteinising hormone, neurotensin, and calcitonin (table 2). Mouse monoclonal antibodies were used to detect expression of serotonin (5-HT), carcinoembryonic antigen (CEA), cytokeratin, S100 protein, and neurofilament. Appropriate positive and negative controls were used.

### Pathological findings

#### GROSS PATHOLOGY

The mass was a  $10 \times 8 \times 6$  cm encapsulated tumour with a smooth surface, weighing 280 g. The cut surface revealed white, tan and yellow, medium hard and partially necrotic tissue.

#### LIGHT MICROSCOPY

Tumour tissue was separated by dense fibrous stroma and contained organoid lobules. Some areas were necrotic. The lobules were com-

posed of tubular gland-like structures and squamoid components (fig 1). Partial gland-like structures formed lumina. The cells forming a tubular pattern had indistinct cell borders and eosinophilic cytoplasm. They had moderately round nuclei with coarse clumped chromatin and distinct borders. The squamoid cells were elongated with abundant eosinophilic cytoplasm. Adjacent to the tubular structures were small round or polygonal cells, with hyperchromatic nuclei and finely dispersed chromatin. There was a transition between small round cells and gland-like cells. Mitotic figures were frequent. The tumour tissue invaded the connective tissue of the capsule and the surrounding pancreatic tissue (fig 2). The pancreatic tissue showed increased fibrous stroma. Pancreatic acini showed extensive atrophy. PAS positive, diastase resistant granules were seen in acinar structures. The cytoplasm of the small round cells and a few of the squamoid cells was positive on staining with Grimelius argyrophil stain.

#### IMMUNOHISTOCHEMICAL STAINING

The tumour tissue displayed fine granular cytoplasmic deposition of NSE in small round cells and in areas of the squamoid components. The cytoplasm of the small round cells was positive for insulin, glucagon, somatostatin, pancreatin polypeptide, TSH, FSH, and neurotensin. The tubular structures were weakly positive for CEA. Staining with all of the other antibodies was negative.

### Discussion

On routine light microscopy, the pancreatoblastoma seemed to be composed of organoid structures, foci of squamous components and gland-like structures. Several other investigators found the acinar structures with PAS positive granules, later confirmed to be trypsinogen. Benjamin and Wright<sup>4</sup> reported that their tumour contained  $\alpha$ -1-antitrypsin and speculated that this might be a marker of acinar differentiation.<sup>4</sup>

Taxy<sup>5</sup> examined a pancreatoblastoma using electron microscopy, but was unable to demonstrate the presence of an islet cell component. John *et al*<sup>6</sup> detected insulin expression by immunoperoxidase and ultrastructural analyses. We found that the small round cells expressed insulin, glucagon, somatostatin, pancreatin polypeptide, TSH, FSH, and neurotensin. We confirmed that the pancreatoblastoma not only had an islet cell component but also contained other endocrine components.

Dayal and O'Brian<sup>6</sup> suggested that the exocrine and endocrine pancreatic tissue in pancreatoblastoma originate from tubi of pancreas, pancreatic exocrine components from the tubular end, and pancreatic endocrine components from the paratubi. We agree that pancreatoblastoma is an embryonal neoplasm arising from multipotential stem cells that mimic the embryogenesis of the pancreas with acinar and endocrine cells developing from primitive ducts.<sup>7</sup>

Using immunohistochemistry we demonstrated the expression of TSH, FSH and

neurotensin by tumour cells. We believe that these are primitive neoplastic endocrine components. During the differentiation process, these cells synthesise and secrete these hormones abnormally. These results provide further evidence that pancreatoblastoma is an embryonal neoplasm arising from multipotential stem cells.

We reviewed the literature and found 14 cases of pancreatoblastoma with adequate morphological description of the lesion.<sup>3-10</sup> The ages of the patients ranged from 15 months to 13 years (average 5.5 years). More boys were affected than girls. Tumour were generally large (average 10.2 cm). There was no evidence of metastasis prior to surgery in any of the patients. Two died.<sup>1,8</sup> The longest follow up period was 16 years.

Our patient was followed for five years and there is no evidence of recurrence. As the tumour was encapsulated, it could be removed completely and had more favourable prognosis than pancreatic carcinoma in adults.

In conclusion, we believe that pancreatoblastoma is a unique primary pancreatic neoplasm

in infants and children. This tumour, which arises from primitive multipotential stem cells, has better prognosis than pancreatic carcinomas in adults.

The authors thank Dr Chen Jia Jun, Department of Physiology, Qingdao Medical College, for providing the antisera.

- 1 Frable WJ, Still WJS, Kay S. Carcinoma of the pancreas, infantile type. *Cancer* 1971;27:667-73.
- 2 Horie A, Hoshinobu Y, Kotoo Y, Mirva A. Morphogenesis of pancreatoblastoma, infantile carcinoma of the pancreas. *Cancer* 1977;39:247-54.
- 3 John JB, Frederick MC, Hirikati SN. Pancreatoblastoma; A histochemical and ultrastructural analysis. *Cancer* 1984;53:963-9.
- 4 Benjamin E, Wright DH. Adenocarcinoma of the pancreas of childhood: A report of two cases. *Histopathology* 1980;4:87-104.
- 5 Taxy JB. Adenocarcinoma of the pancreas in childhood. *Cancer* 1976;37:1508-18.
- 6 Dayal Y, O'Brian DS. The pathology of the pancreatic endocrine cells. In: Delellis RA, ed. *Diagnostic immunohistochemistry*. Masson Publishing, 1981:111-35.
- 7 Mikiro I, Toshio S, Yukihiko K. Alpha-fetoprotein-producing pancreatoblastoma: A case report. *Cancer* 1986;57:1833-5.
- 8 Cubilla AL, Fitzgerald PJ. Classification of pancreatic cancer (nonendocrine). *Mayo Clin Proc* 1979;54:449-58.
- 9 Xian-Qing M. Pancreatoblastoma—infantile carcinoma of the pancreas. *Chinese J Pathol* 1983;1:22.
- 10 Jia Yu. Pancreatoblastoma: A case report. *Chinese J Pathol* 1987;2:143.